

Acquired Macular Disorders

- **INTRODUCTION** 390
 - Applied anatomy 390
 - Clinical evaluation 391
- **FUNDUS ANGIOGRAPHY** 393
 - Fluorescein angiography 393
 - Indocyanine green angiography 401
- **LASER PHOTOCOAGULATION** 402
- **AGE-RELATED MACULAR DEGENERATION** 405
 - Introduction 405
 - Drusen 405
 - Atrophic age-related macular degeneration 407
 - Retinal pigment epithelial detachment 410
 - Retinal pigment epithelial tear 410
 - Exudative age-related macular degeneration 411
- **AGE-RELATED MACULAR HOLE** 418
- **CENTRAL SEROUS RETINOPATHY** 421
- **CYSTOID MACULAR OEDEMA** 423
- **MYOPIC MACULOPATHY** 425
- **MACULAR EPIRETINAL MEMBRANE** 427
- **ANGIOID STREAKS** 428
- **CHOROIDAL FOLDS** 430
- **DRUG-INDUCED MACULOPATHIES** 431
 - Antimalarials 431
 - Phenothiazines 433
 - Toxic crystalline maculopathies 433
- **MISCELLANEOUS MACULOPATHIES** 434
 - Idiopathic polypoidal choroidal vasculopathy 434
 - Maculopathy in optic disc pit 435
 - Solar maculopathy 436
 - Cancer-associated retinopathy 436
 - Valsalva maculopathy 436

Introduction

Applied anatomy

Landmarks (Figs 13.1 and 13.2)

1. **The macula** is a round area at the posterior pole measuring approximately 5.5 mm in diameter. Histologically, it contains xanthophyll pigment and more than one layer of ganglion cells.
2. **The fovea** is a depression in the inner retinal surface at the centre of the macula with a diameter of 1.5 mm (about one disc) (Fig. 13.3). Ophthalmoscopically it gives

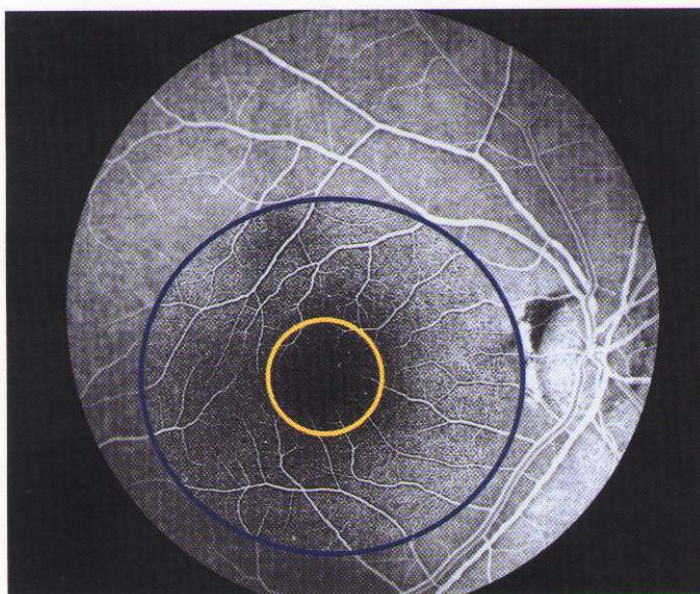


Fig. 13.1
Anatomical landmarks. Macula (blue circle); fovea (yellow circle)

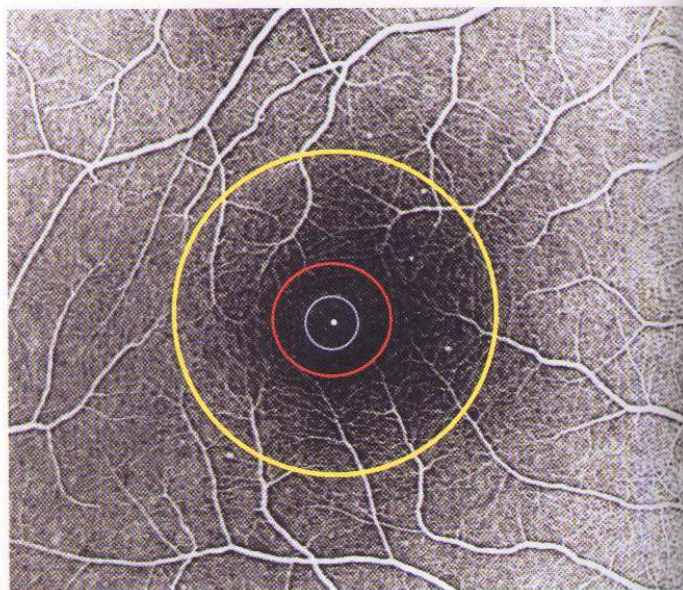


Fig. 13.2
Anatomical landmarks. Fovea (yellow circle); foveal avascular zone (red circle); foveola (lilac circle); umbo (central white spot)

rise to an oval light reflex (Fig. 13.4) because of the increased thickness of the retina and internal limiting membrane at its border.

3. **The foveola** forms the central floor of the fovea and has a diameter of 0.35 mm. It is the thinnest part of the retina, is devoid of ganglion cells and consists only of cones and their nuclei.
4. **The foveal avascular zone (FAZ)** is located within the fovea but extends beyond the foveola. The exact diameter is variable and its location can be determined with accuracy only by fluorescein angiography (Fig. 13.5).
5. **The umbo** is a tiny depression in the very centre of the foveola which corresponds to the foveolar reflex, loss of which may be an early sign of damage.

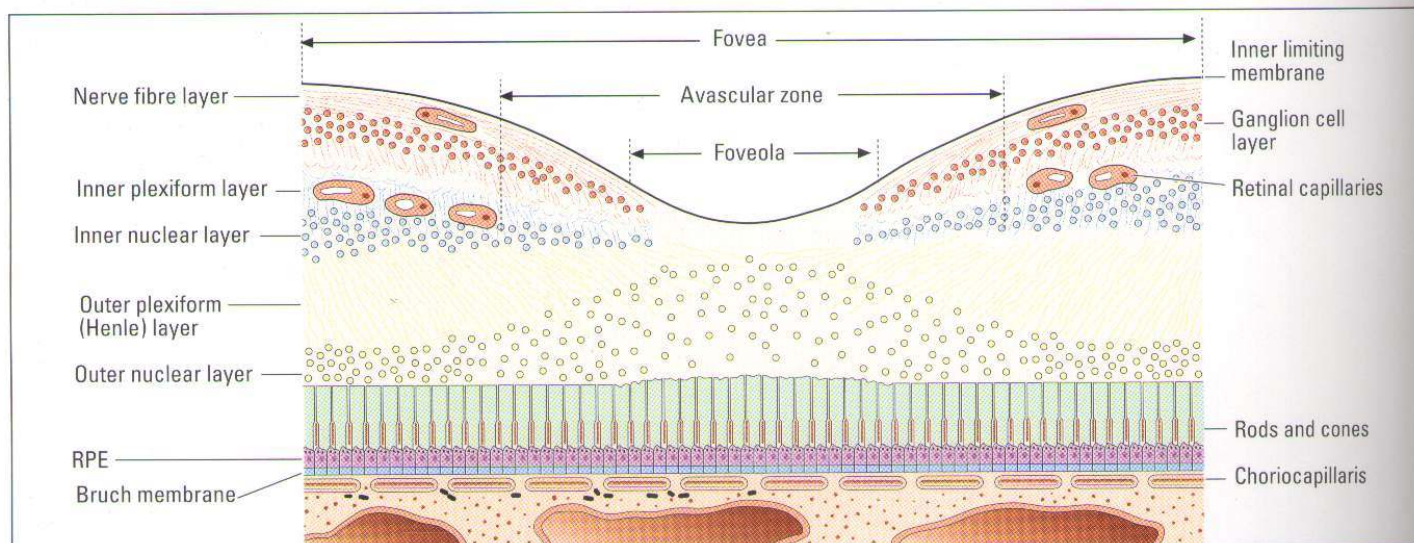


Fig. 13.3
Cross-section of the fovea

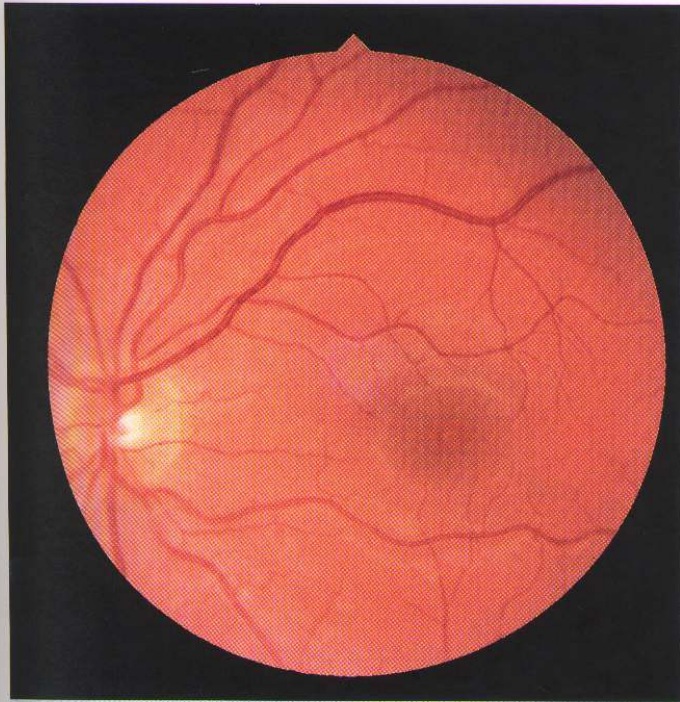


Fig. 13.4
Normal foveal light reflex

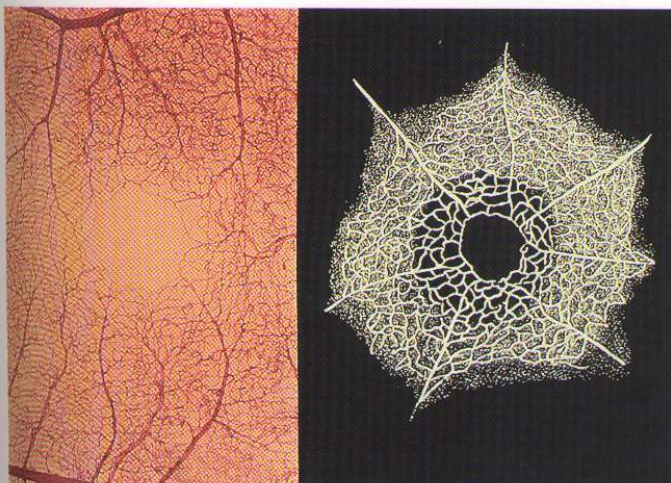


Fig. 13.5
Foveal avascular zone (Courtesy of Wilmer Eye Institute)

Retinal pigment epithelium (RPE)

The retinal pigment epithelium (RPE) is a single layer of hexagonal cells, the apices of which manifest villous processes that envelop the outer segments of the photoreceptors. The RPE cells at the fovea are taller, thinner and contain more and larger melanosomes than elsewhere in the retina. The adhesion between the RPE and sensory retina is weaker than between the RPE and Bruch membrane, which underlies the RPE. The potential space between the RPE and sensory retina is the subretinal space. The RPE maintains the integrity (i.e. dryness) of the subretinal space in two ways:

- The RPE cells and the intervening tight junctional complexes (zonula occludentes) constitute the outer blood-retinal barrier (see Fig. 13.12), which prevents

extracellular fluid, which normally leaks from the choriocapillaris from entering the subretinal space.

- It also actively pumps ions and water out of the subretinal space.

Bruch membrane

This separates the RPE from the choriocapillaris. On electron microscopy it consists of five elements:

- Basal lamina of the RPE.
- Inner collagenous layer.
- Thicker band of elastic fibres.
- Outer collagenous layer.
- Basal lamina of the outer layer of the choriocapillaris.

Changes in Bruch membrane are relevant to the pathogenesis of many macular disorders.

Clinical evaluation

Symptoms

1. **Impairment of central vision** is the main symptom. Patients with macular disease complain of 'something obstructing central vision' (positive scotoma) in contrast with those with optic neuropathy, who may notice a hole in their vision (negative scotoma).
2. **Metamorphopsia**, distortion of perceived images, is a common symptom not present in optic neuropathy.
3. **Micropsia**, a decrease in image size caused by spreading apart of foveal cones, is less common.
4. **Macropsia**, an increase in image size due to crowding together of foveal cones, is uncommon.

NB: Colour desaturation is not present in mild macular disease, but is common in early optic nerve disease.

Clinical examination

1. **Visual acuity** is the most important test of macular function, particularly for near. In patients with macular

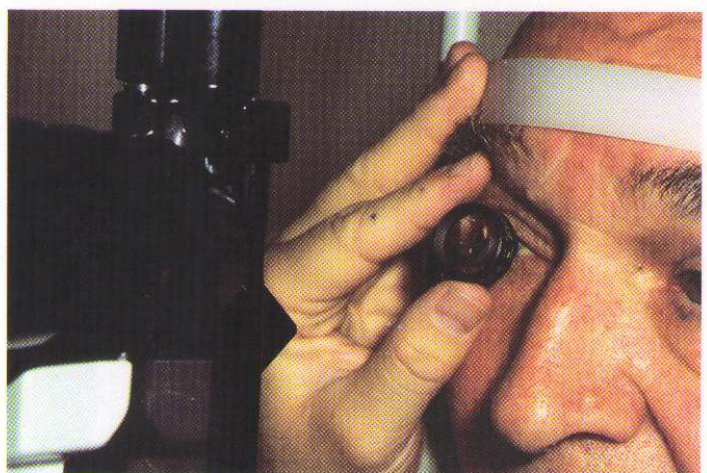


Fig. 13.6
Slit-lamp indirect biomicroscopy

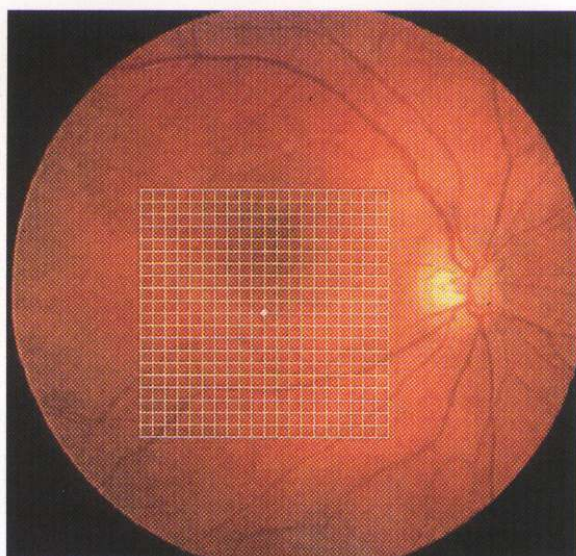


Fig. 13.7
Amsler grid superimposed on the retina (Courtesy of A. Franklin)




Fig. 13.8
Amsler grid chart 1 (Courtesy of A. Franklin)

disease visual acuity is frequently worse when the patient looks through a pinhole.

- 2. Slit-lamp indirect biomicroscopy** with a contact lens or a strong convex lens affords excellent visualization of the

macula (Fig. 13.6). Monochromatic light is useful in detecting subtle lesions which may otherwise be overlooked. Green (red-free) light may also enhance detection of superficial retinal lesions such as wrinkling of




Chart 2




Chart 3




Chart 4




Chart 5




Chart 6

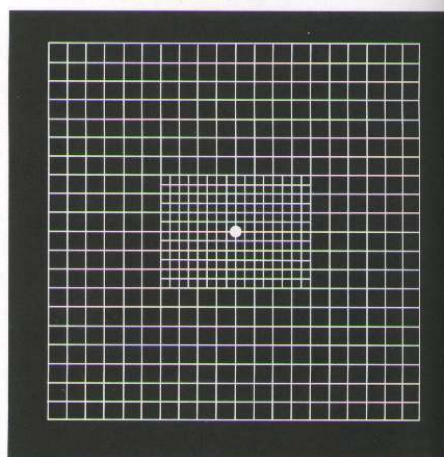


Chart 7

Fig. 13.9
Amsler grid charts 2–7 (Courtesy of A. Franklin)

the internal limiting membrane or cystoid oedema. It is also useful in delineating the outline of subtle serous elevations of the sensory retina. Lesions involving the RPE and choroid are best detected using light at the red end of the spectrum.

3. **Amsler grid** testing evaluates the 10° of the visual field surrounding fixation (Fig. 13.7) and is useful for both screening and monitoring macular disease. There are seven charts, each consisting of a 10 cm square (Figs 13.8 and 13.9).

- Chart 1** is divided into 400 smaller 5 mm squares. When viewed at one-third of a metre, each small square subtends an angle of 1° .
- Chart 2** is similar to chart 1 but has diagonal lines that aid fixation in patients unable to see the central spot.
- Chart 3** is identical to chart 1 but has red squares which may be helpful in detecting colour desaturation in patients with optic nerve lesions.
- Chart 4** consisting of random dots is seldom used.
- Chart 5** consists of horizontal lines and is designed to detect metamorphopsia along specific meridia, especially horizontally to investigate difficulties with reading.
- Chart 6** is similar to chart 5 but has a white background and the central lines are closer together.
- Chart 7** exhibits a fine central grid, each square subtending an angle of $1/2^\circ$ and is therefore more sensitive.

The test is performed as follows:

- The patient wears reading spectacles, if appropriate, and covers one eye.

- The patient is asked to look directly at the centre dot with the uncovered eye and report any distortion, blurred areas or blank spots anywhere on the grid.
- Patients with maculopathy often report that the lines are wavy whereas those with optic neuropathy often remark that some of the lines are missing or faint but not distorted (Fig. 13.10).

4. **Photostress testing** may be useful to detect maculopathy when ophthalmoscopy is equivocal and also to differentiate macular disease from optic neuropathy. It is performed as follows:

- The best corrected distance visual acuity is determined.
- The patient fixates the light of a pen-torch or an indirect ophthalmoscope held about 3 cm away for about 10 seconds.
- The photostress recovery time (PSRT) is the time taken to read any three letters of the pre-test acuity line and is normally between 15 and 30 seconds.
- The test is performed on the other, presumably normal, eye and the results are compared.

The PSRT is prolonged, relative to the normal eye, in macular disease (sometimes 50 seconds or more) but not in optic neuropathy.

5. **Pupillary light reactions** are usually normal in eyes with macular disorders, in contrast to mild lesions of the optic nerve, in which a relative afferent pupillary defect occurs early (see Chapter 18).

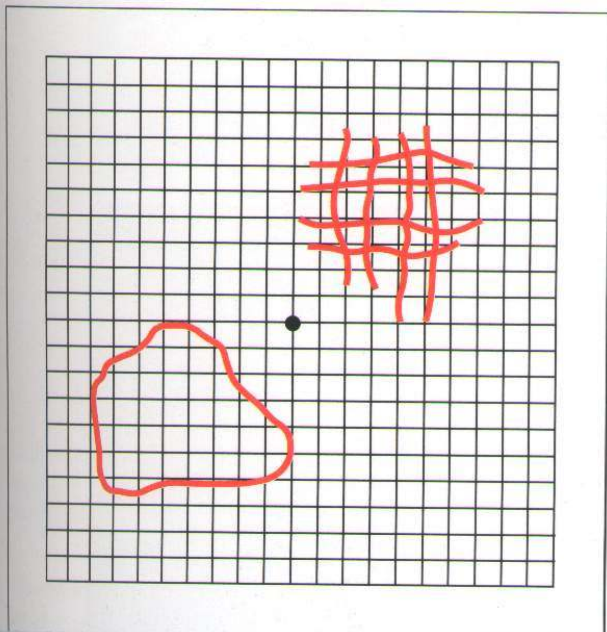


Fig. 13.10
Amsler recording chart on which a patient has drawn to indicate metamorphopsia and a relative scotoma (Courtesy of A. Franklin)

Fundus angiography

Fluorescein angiography

General principles

- Fluorescein** is an orange water-soluble dye that when injected intravenously remains largely intravascular and circulates in the bloodstream.
- Fluorescein angiography (FA)** involves photographic surveillance of the passage of fluorescein through the retinal and choroidal circulations.
- Fluorescein binding.** On intravenous injection, between 70% and 85% of fluorescein molecules bind to serum proteins (bound fluorescein); the remainder remain unbound (free fluorescein) (Fig. 13.11).
- The outer blood-retinal barrier.** The major choroidal vessels are impermeable to both bound and free fluorescein. However, the walls of the choriocapillaris are extremely thin and contain multiple fenestrations (Fig. 13.12a) through which free fluorescein molecules escape into the extravascular space, from which they pass across Bruch membrane. However, on reaching the RPE, they encounter tight junctional intercellular complexes termed zonula occludentes, which prevent the passage of free fluorescein molecules across the RPE (Fig. 13.12b).

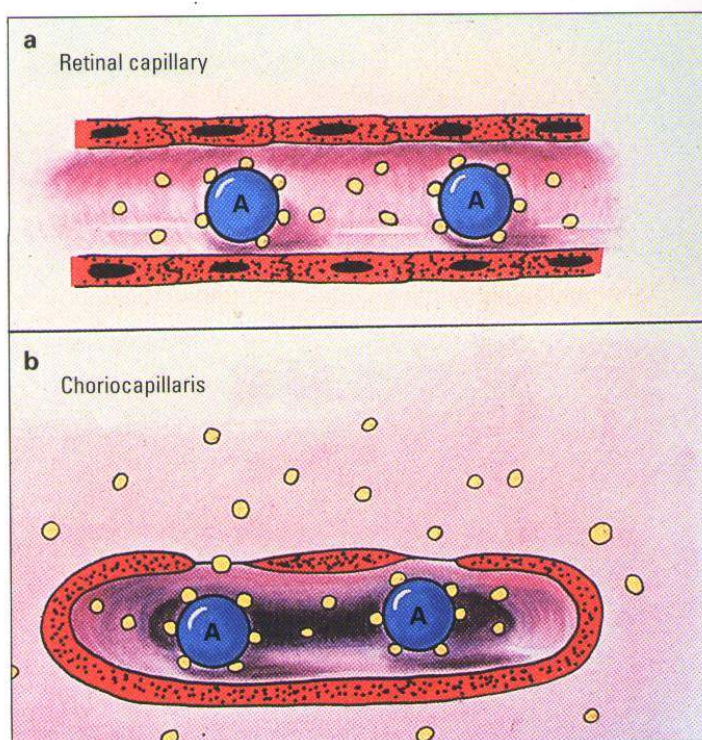


Fig. 13.11
Fluorescein binding and permeability (A = albumin) (see text)
(Courtesy of Wilmer Institute)

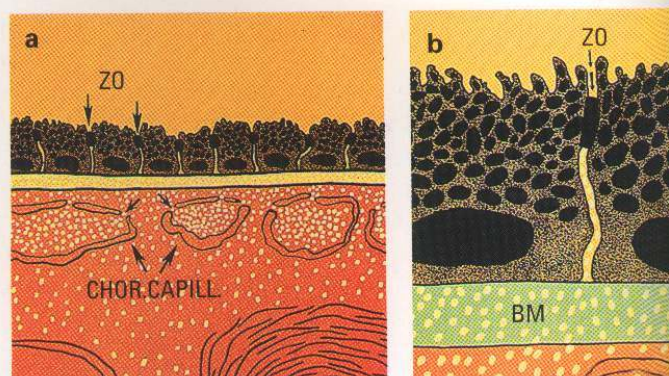


Fig. 13.12
Outer blood-retinal barrier (ZO = zonula occludentes;
BM = Bruch membrane) (see text) (Courtesy of Wilmer Institute)

5. The inner blood-retinal barrier is composed of the tight junctions between retinal capillary endothelial cells across which neither bound nor free fluorescein can pass (Fig. 13.13a and b). Fluorescein is therefore confined to within the lumen of the retinal capillaries. The basement membrane and pericytes play only a minor role in this regard. Disruption of the inner blood-retinal barrier will permit leakage of both bound and free fluorescein molecules into the extravascular space (Fig. 13.13c and d).

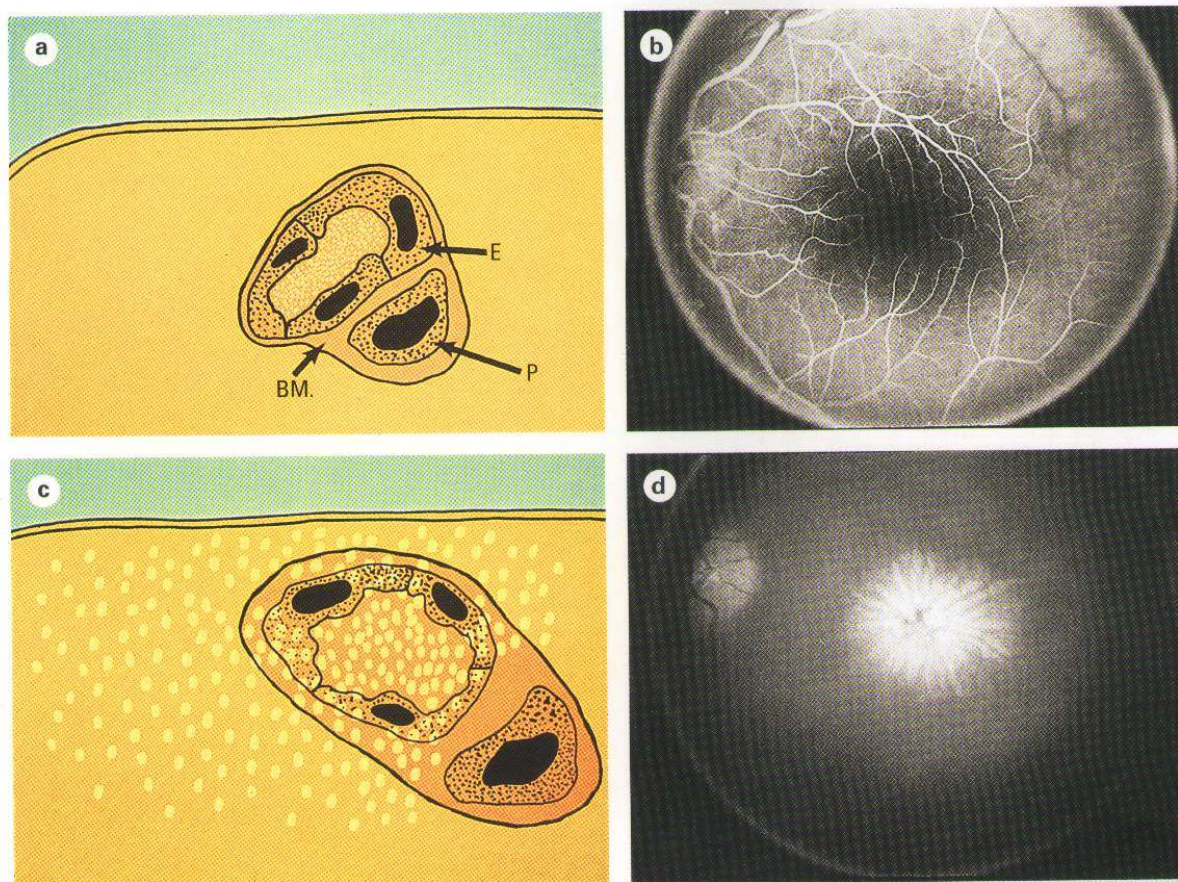


Fig. 13.13
Inner blood-retinal barrier. (a) Intact barrier without leakage of fluorescein (BM = basement membrane, P = pericyte, E = endothelial cell); (b) FA showing absence of leakage; (c) disrupted barrier with leakage of fluorescein; (d) FA showing leakage (Courtesy of Wilmer Institute)

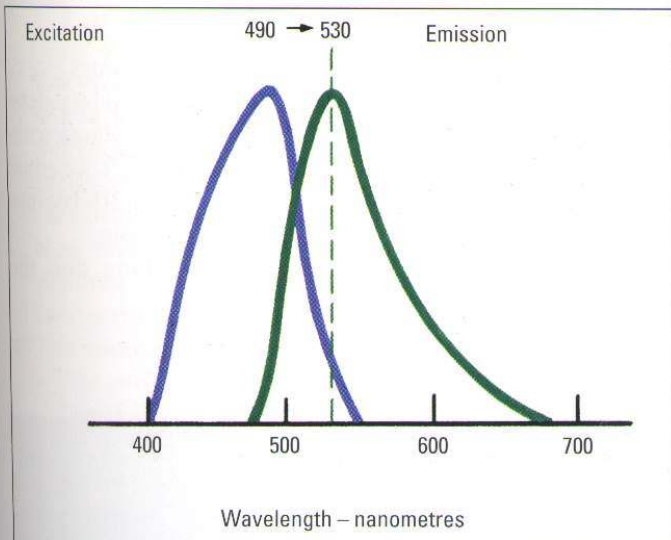


Fig. 13.14
Excitation and emission of fluorescence

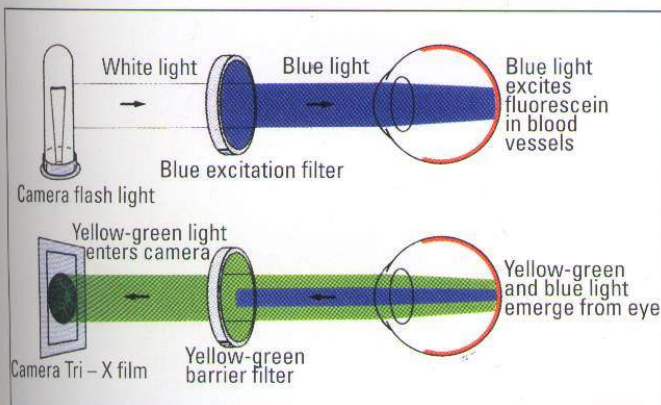


Fig. 13.15
Photographic principles of FA

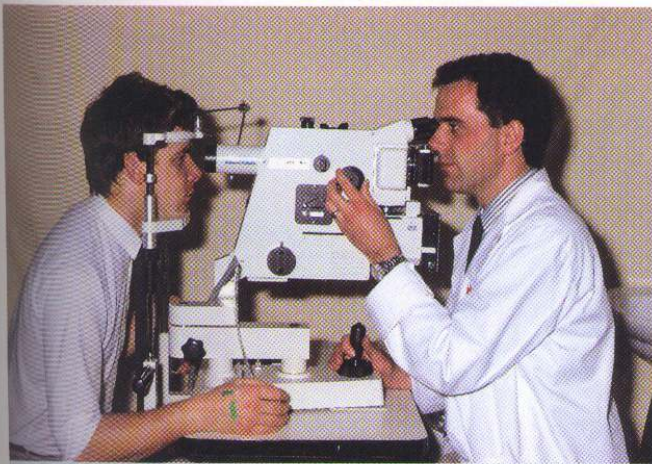

Fig. 13.16
Position of patient for FA

6. Fluorescence is the property of certain molecules to emit light energy of a longer wavelength when stimulated by light of a shorter wavelength (Fig. 13.14). The excitation peak for fluorescein is about 490 nm (blue part of the spectrum) and represents the maximal absorption of light energy by fluorescein. Molecules stimulated by this

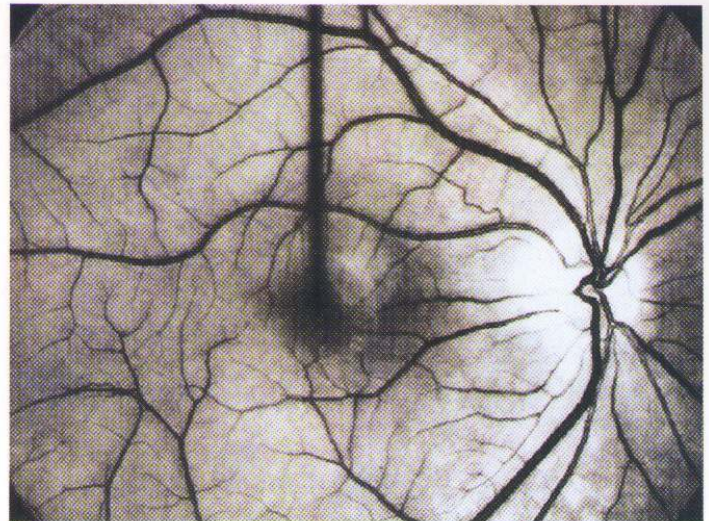


Fig. 13.17
Red-free photograph

wavelength will be excited to a higher energy level and will emit light of a longer wavelength (green part of the spectrum) at about 530 nm.

7. Filters of two types are used to ensure that blue light enters the eye and only yellow-green light enters the camera (Fig. 13.15).

- A blue excitation filter* through which passes white light from the camera flash. The emerging blue light enters the eye and excites the fluorescein molecules in the retinal and choroidal circulations, which then emit light of a longer wavelength (yellow-green).
- A yellow-green barrier filter* then blocks any reflected blue light from the eye, allowing only yellow-green light to pass through unimpeded to be recorded on film.

Photographic technique

A good-quality angiogram requires adequate pupillary dilatation and clear media.

- The patient is seated in front of the fundus camera (Fig. 13.16).
- Fluorescein, usually 5 ml of a 10% solution, is drawn up into a syringe. In eyes with opaque media, 3 ml of a 25% solution may afford better results.
- A 'red-free' photograph is taken (Fig. 13.17).
- Fluorescein is injected rapidly intravenously.
- Photographs are taken at approximately 1-second intervals, 5–25 seconds after injection.
- After the transit phase has been photographed in one eye, control pictures are taken of the opposite eye. If appropriate, late photographs may also be taken after 10 minutes and, occasionally, 20 minutes if leakage is anticipated.

Adverse effects

Discoloration of skin and urine is almost universal. Mild side effects include nausea, vomiting, flushing of the skin, itching, hives and excessive sneezing. Serious but rare problems

include syncope, laryngeal oedema, bronchospasm and anaphylactic shock.

NB: It is very important to have arrangements for managing these eventualities.

Phases of the angiogram

Fluorescein enters the eye through the ophthalmic artery, passing into the choroidal circulation through the short posterior ciliary arteries and into the retinal circulation through the central retinal artery. Because the route to the retinal circulation is slightly longer than that to the choroidal, the latter is filled about 1 second before the former (Fig. 13.18). In the choroidal circulation, precise details are often not discernible, mainly because of rapid leakage of free fluorescein from the choriocapillaris and also because the melanin in the RPE cells blocks choroidal fluorescence. The angiogram consists of the following overlapping phases: (a) choroidal (pre-arterial), (b) arterial, (c) arteriovenous (capillary) and (d) venous (Fig. 13.19).

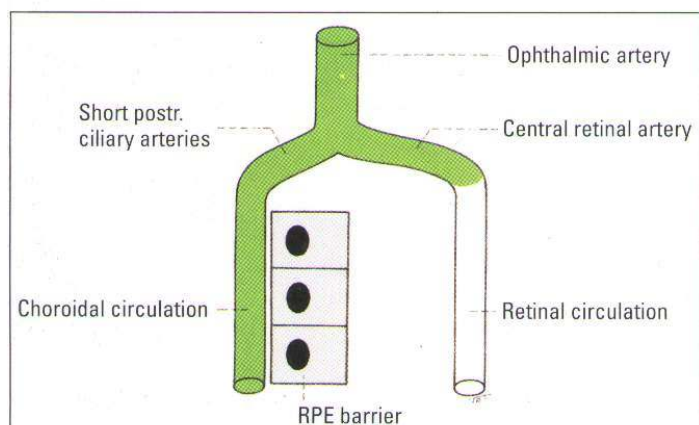


Fig. 13.18
Entry of fluorescein into the choroidal and retinal circulations

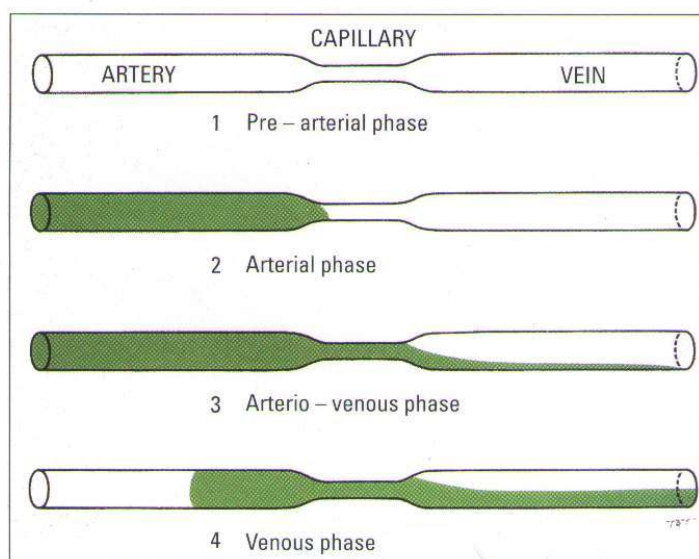


Fig. 13.19
Four phases of the fluorescein angiogram

The normal angiogram

1. **The choroidal (pre-arterial) phase** occurs 8–12 seconds after dye injection and is characterized by patchy filling of the choroid due to leakage of free fluorescein through the fenestrated choriocapillaris. A cilioretinal artery, if present, will fill at this time (Fig. 13.20) because it is derived from the posterior ciliary circulation.
2. **The arterial phase** shows arterial filling and the continuation of choroidal filling (Fig. 13.21).



Fig. 13.20
Choroidal phase showing patchy choroidal filling and filling of a cilioretinal artery

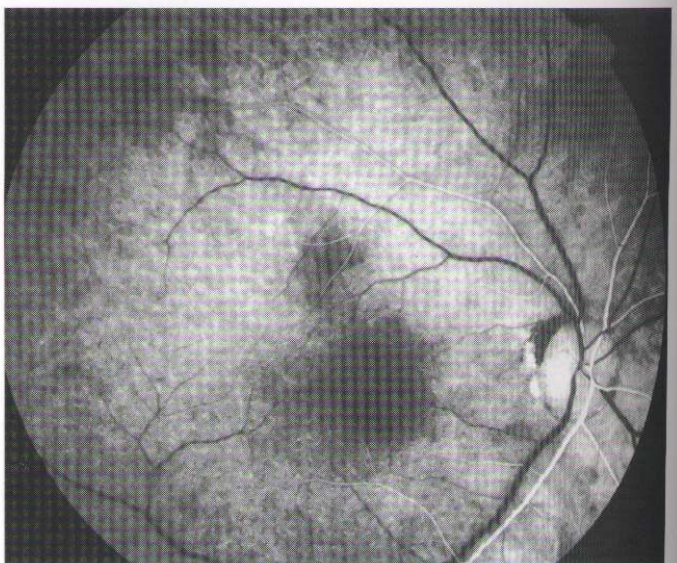


Fig. 13.21
Arterial phase showing filling of the choroid and retinal arteries

3. **The arteriovenous (capillary) phase** shows complete filling of the arteries and capillaries with early laminar flow in the veins in which the dye is seen along the lateral wall of the vein (Fig. 13.22). Choroidal filling continues and background choroidal fluorescence increases as free fluorescein continues to leak from the choriocapillaris into the extravascular space. In hypopigmented eyes, this may be so marked that details of the retinal capillaries may be obscured. In highly pigmented eyes, background choroidal fluorescence will be less obvious.

4. **The venous phase**

- a. *The early phase* exhibits complete arterial and capillary filling, and more marked laminar venous flow (Fig. 13.23).
- b. *The mid phase* displays almost complete venous filling (Fig. 13.24).

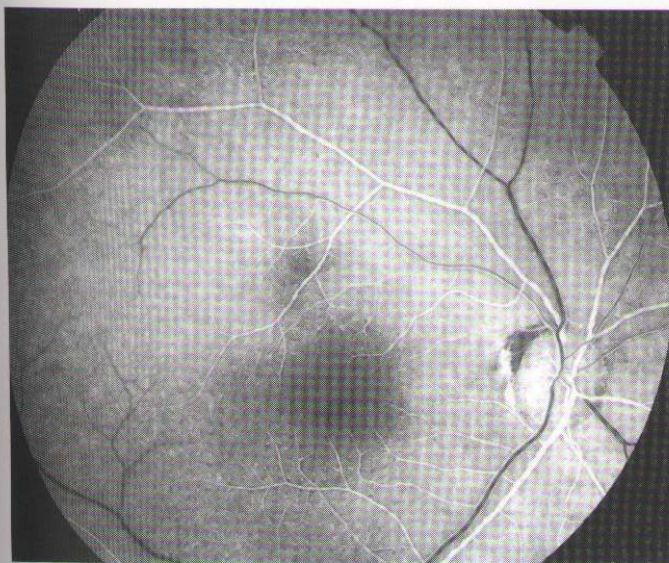


Fig. 13.22
Arteriovenous (capillary) phase showing complete arterial filling and early lamellar venous flow

c. *The late phase* shows complete venous filling with reducing concentration of dye in the arteries.

5. **The late (elimination) phase** demonstrates the effects of continuous recirculation, dilution and elimination of the dye. With each succeeding wave, the intensity of fluorescence becomes weaker. Late staining of the disc is a normal finding (Fig. 13.25). Fluorescein is absent from the angiogram after 5–10 min and is usually totally eliminated from the body within several hours.

Dark appearance of the fovea

The dark appearance of the fovea on FA (Fig. 13.26a) is caused by three phenomena (Fig. 13.26b):

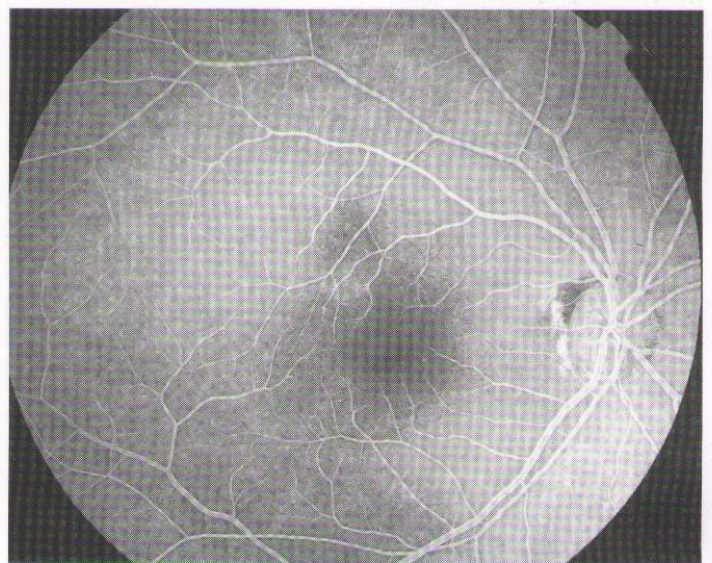


Fig. 13.24
Mid venous phase showing almost complete venous filling

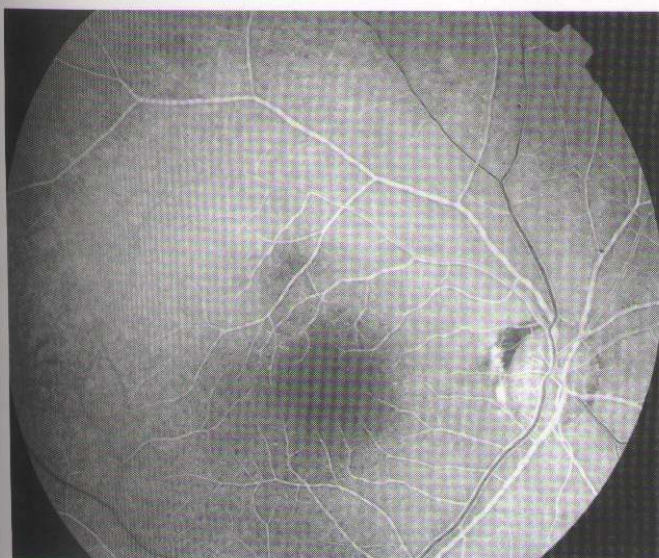

Fig. 13.23
Early venous phase showing marked lamellar venous flow

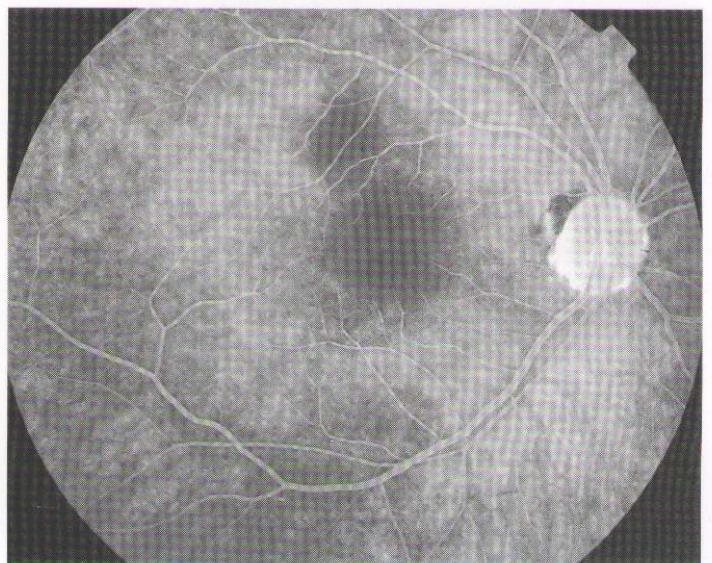


Fig. 13.25
Late (elimination) phase showing weak fluorescence and staining of the optic disc

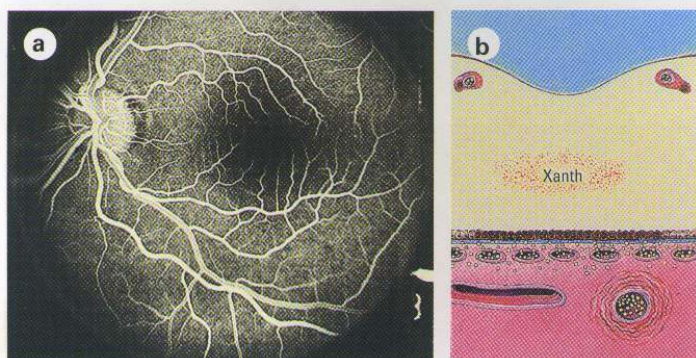


Fig. 13.26
Dark appearance of the fovea on FA (Xanth = xanthophyll)
(see text) (Courtesy of Wilmer Institute)

- Avascularity of FAZ.
- Blockage of background choroidal fluorescence due to increased density of xanthophyll at the fovea.
- Blockage of background choroidal fluorescence by the RPE cells at the fovea, which are large and contain more melanin than those elsewhere.

Causes of hyperfluorescence

Increased fluorescence may be due to enhanced visualization of a normal quantity of fluorescein in the fundus, or an absolute increase in the fluorescein content of the tissues.

1. A transmission (window) defect results from focal RPE atrophy (Fig. 13.27a) or absence, with resultant unmasking of normal background choroidal fluorescence (Fig. 13.27b). It is characterized by early hyperfluorescence which increases in intensity and then fades without changing size or shape.

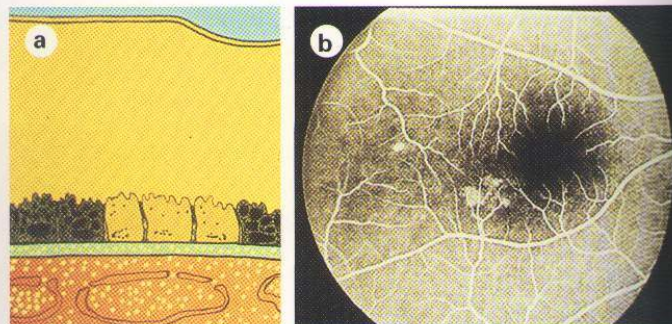


Fig. 13.27
Hyperfluorescence due to a pigment epithelial window defect
(see text) (Courtesy of Wilmer Institute)

2. Pooling of dye in an anatomical space may occur due to breakdown of the outer blood-retinal barrier (RPE tight junctions).

a. In the subretinal space (Fig. 13.28b), as in central serous retinopathy (Fig. 13.28a), it is characterized by early hyperfluorescence (Fig. 13.28c) which increases in both size and intensity (Fig. 13.28d-f).

b. In the sub-RPE space (Fig. 13.29b), as in pigment epithelial detachment (PED) (Fig. 13.29a), it is characterized by early hyperfluorescence (Fig. 13.29c) which increases in intensity but not in size (Fig. 13.29d).

3. Leakage of dye may occur from:

a. Abnormal choroidal vasculature, such as choroidal neovascularization (CNV) (Fig. 13.30a), is characterized by an early lacy filling pattern of hyperfluorescence (Fig. 13.30b) which increases in size and intensity (Fig. 13.30c and d).

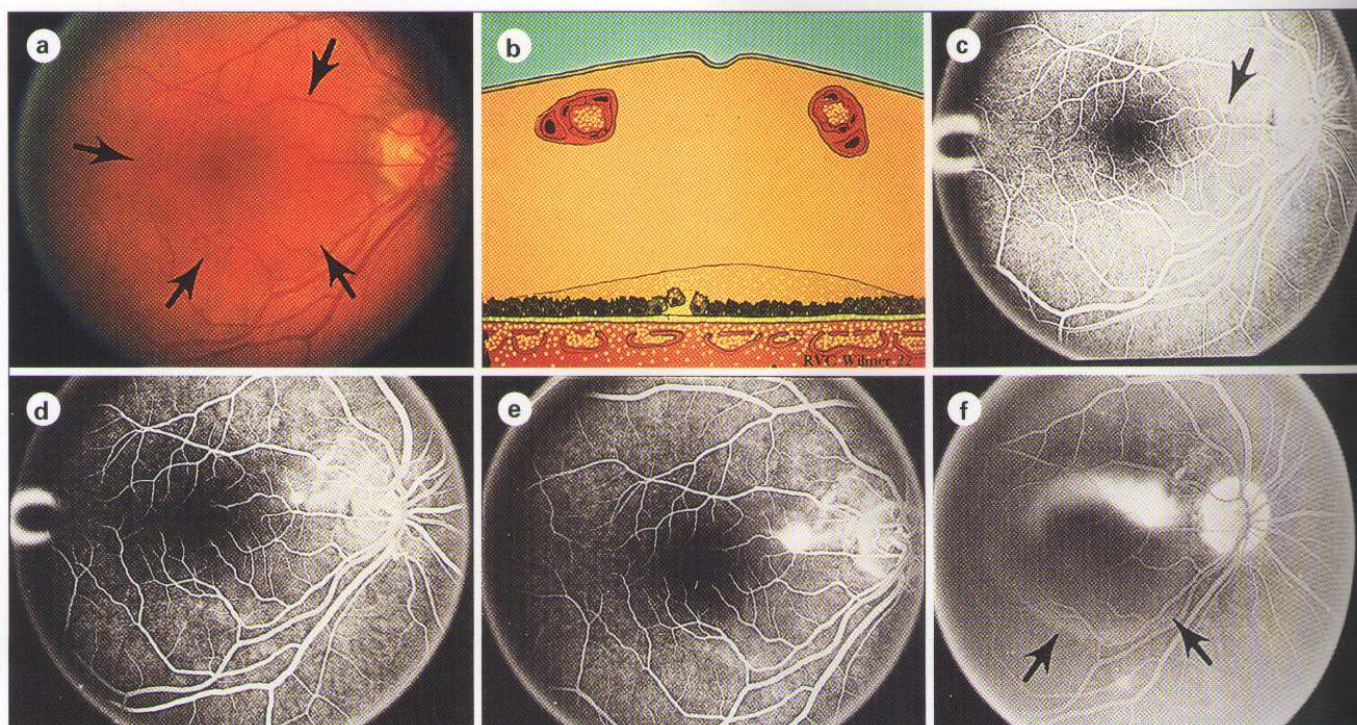


Fig. 13.28
Hyperfluorescence due to pooling of dye in the subretinal space in central serous retinopathy (see text) (Courtesy of Wilmer Institute)

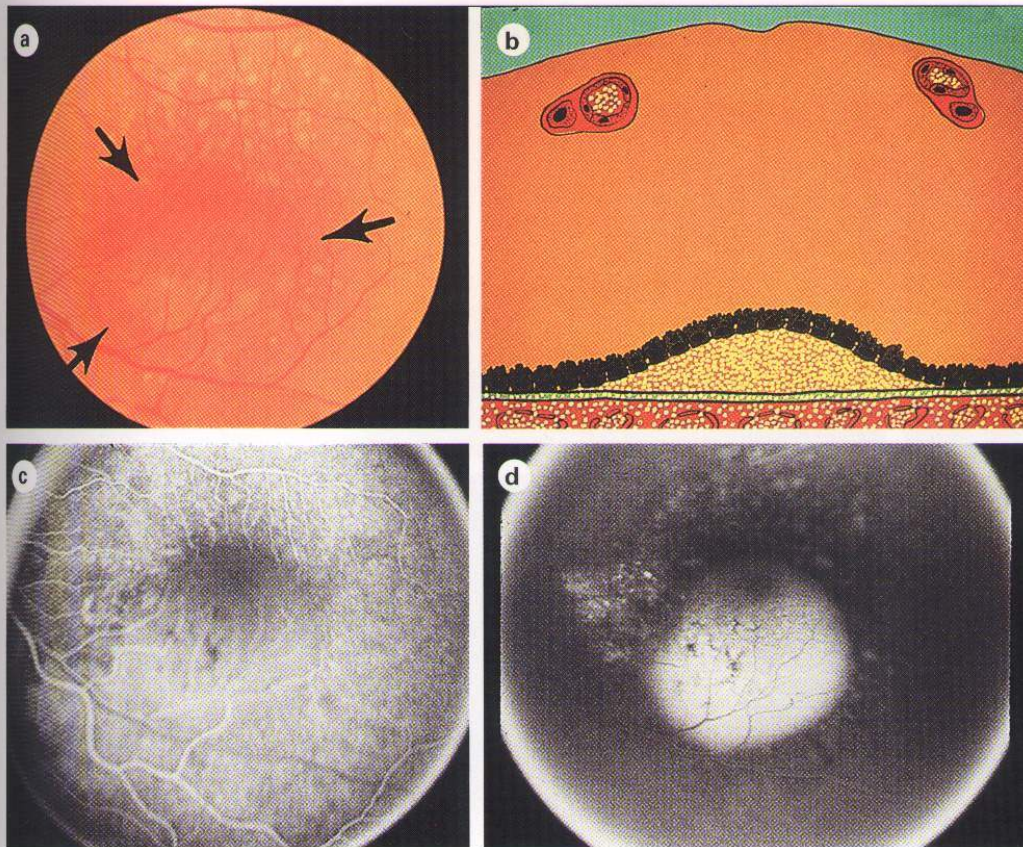


Fig. 13.29
Hyperfluorescence due to pooling of dye in the subpigment epithelial space in PED (see text)
(Courtesy of Wilmer Institute)

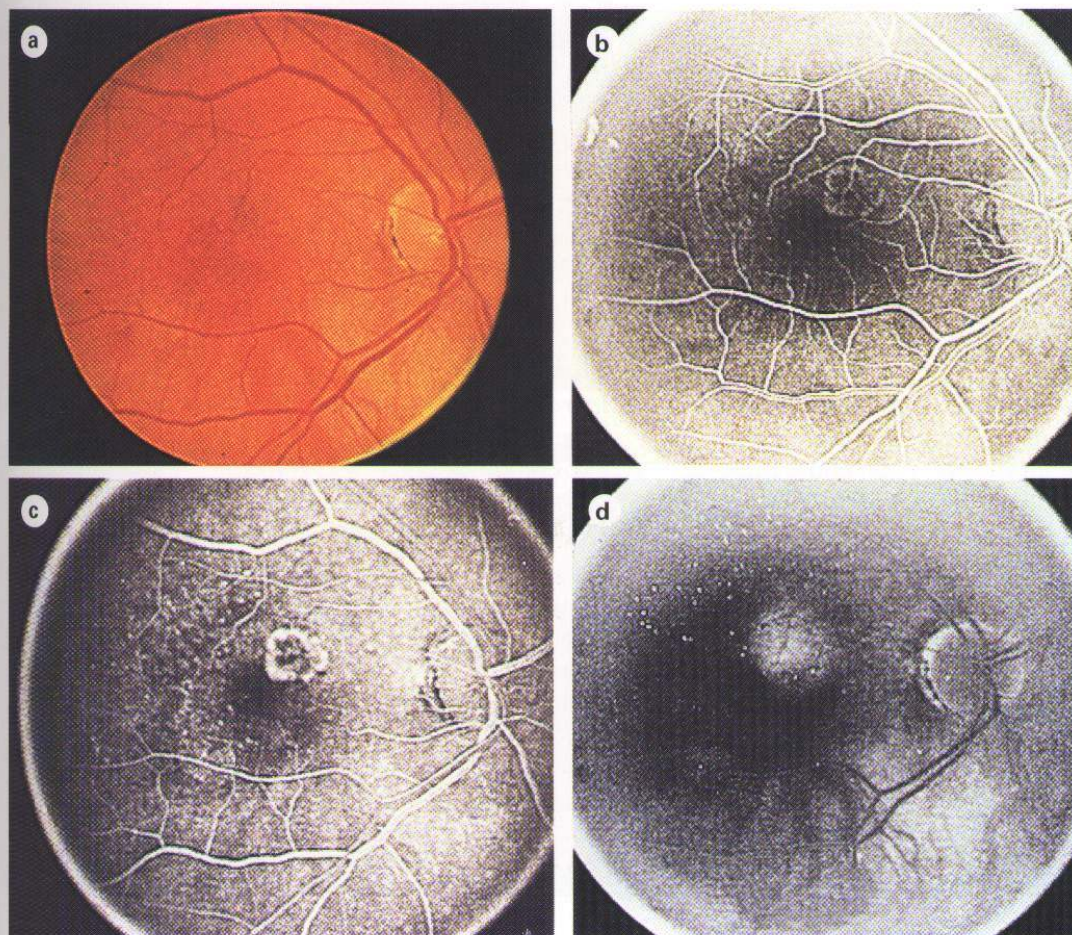
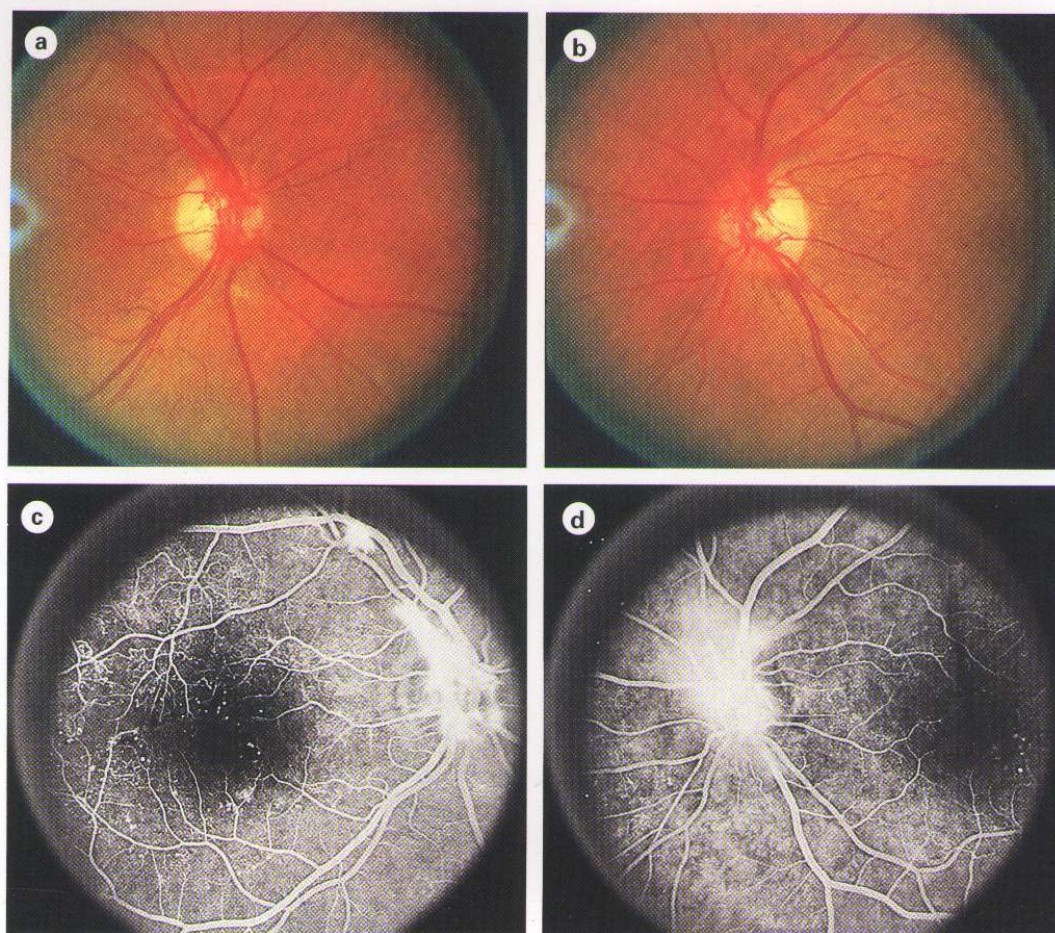


Fig. 13.30
Hyperfluorescence due to leakage from choroidal neovascularization (see text)
(Courtesy of Wilmer Institute)

**Fig. 13.31**

Hyperfluorescence due to leakage from disc new vessels in proliferative diabetic retinopathy (see text) (Courtesy of Wilmer Institute)

- b. Breakdown of the inner blood–retinal barrier*, as in cystoid macular oedema, is characterized by hyperfluorescence beginning in the arteriovenous phase, which increases in size and intensity, giving rise to the characteristic ‘flower-petal’ pattern seen in the late phase (see Fig. 13.13d).
 - c. Abnormal retinal or disc vasculature*, as in proliferative diabetic retinopathy (Fig. 13.31a and b), is characterized by early hyperfluorescence due to rapid filling of the new vessels followed by increasing intense hyperfluorescence due to leakage (Fig. 13.31c and d).
- 4. Staining** of tissues as a result of prolonged retention of dye (e.g. drusen) may be seen in the late phase of the angiogram after the dye has left the choroidal and retinal circulations.

Causes of hypofluorescence

Reduction or absence of fluorescence may be due to (a) *blockage* (masking) of a normal quantity of fluorescein in a tissue (Fig. 13.32) or (b) *filling defects* of a tissue with resultant low fluorescein content.

- 1. Blockage of retinal fluorescence** may be caused by lesions anterior to the retina. This may involve the large superficial vessels, capillaries or both, depending on the location of the lesion as follows:

- a. Vitreous opacities and preretinal lesions* such as blood (Fig. 13.33a) will block all fluorescence (Fig. 13.33b).
- b. Deep retinal lesions* such as intraretinal haemorrhages and hard exudates will block only capillary fluorescence, sparing that from the larger retinal vessels.

- 2. Blockage of background choroidal fluorescence** is caused by all conditions that block retinal fluorescence as well as the following which block only choroidal fluorescence:

- a. Subretinal or sub-RPE lesions* such as blood (Fig. 13.34).
- b. Increased density of the RPE* such as in congenital hypertrophy of the RPE (Fig. 13.35).
- c. Choroidal lesions* such as naevi.

- 3. Filling defects** may result from:

- a. Vascular occlusion* which prevents access of dye to the tissues. The occlusion may involve the choroidal circulation or the retinal arteries, veins or capillaries (capillary drop-out) (see Fig. 14.13).
- b. Loss of the vascular bed* which may occur in severe myopic degeneration or choroideremia (see Fig. 15.60).

Stepwise approach to reporting angiograms

A fluorescein angiogram should be interpreted systematically to optimize diagnostic accuracy, as follows:

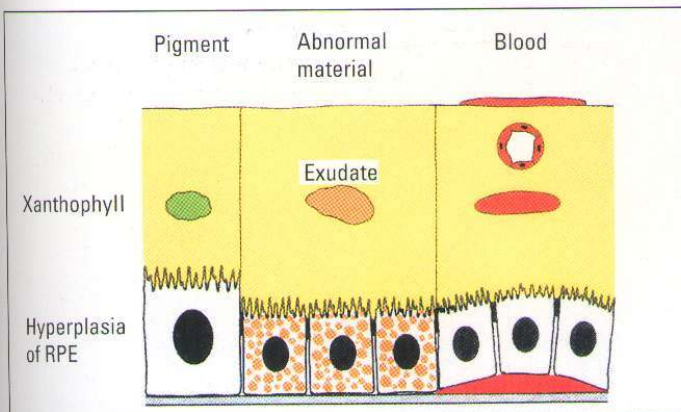


Fig. 13.32
Causes of blocked fluorescence (see text)

1. Comment on the red-free photograph.
2. Indicate the phase of the angiogram.
3. Indicate any hyper- or hypofluorescence and any delay in filling.
4. Indicate any characteristic features such as a smoke-stack or lacy filling pattern (see later).
5. Indicate any change in the area or intensity of fluorescence.

NB: It is important to take into consideration the patient's history and ophthalmoscopic findings before drawing conclusions from the angiogram.

Indocyanine green angiography

General principles

While FA is an excellent method of showing the retinal circulation against the uniform dark background of the RPE, it is not helpful in delineating the choroidal circulation. In contrast, indocyanine green (ICG) angiography is of particular value in studying the choroidal circulation and is a useful adjunct to FA in the investigation of macular disease.

1. **ICG binding.** About 98% of ICG molecules bind with serum proteins (mainly albumin) on entering the circulation. This phenomenon reduces the passage of ICG through the fenestrations of the choriocapillaris, which are impermeable to albumin.
2. **Fluorescence** of ICG is only 1/25 that of fluorescein. The excitation peak is at 805 nm and emission at 835 nm, in the near-infrared spectrum. Infrared light absorbed and emitted by the dye readily penetrates normal ocular pigments such as melanin and xanthophyll, as well as exudates or thin layers of subretinal blood. The filters used are infrared barrier and excitation.

Photographic technique

1. ICG powder is mixed with aqueous solvent to provide 40 mg in 2 ml.

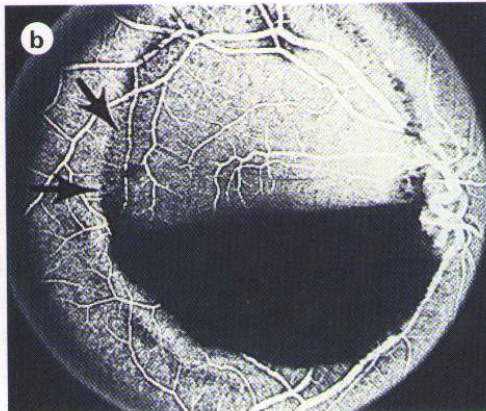
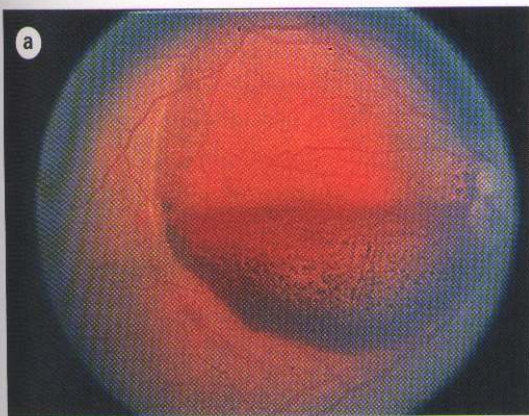


Fig. 13.33
Hypofluorescence due to blockage of all fluorescence by a preretinal haemorrhage (see text) (Courtesy of Wilmer Institute)

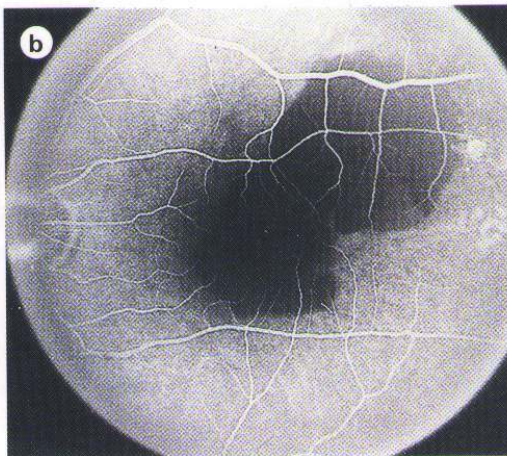
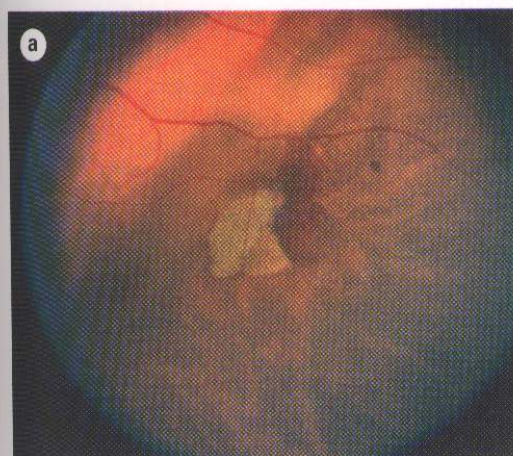


Fig. 13.34
Hypofluorescence due to blockage of background choroidal fluorescence by subretinal pigment epithelial and subretinal haemorrhages (see text) (Courtesy of Wilmer Institute)

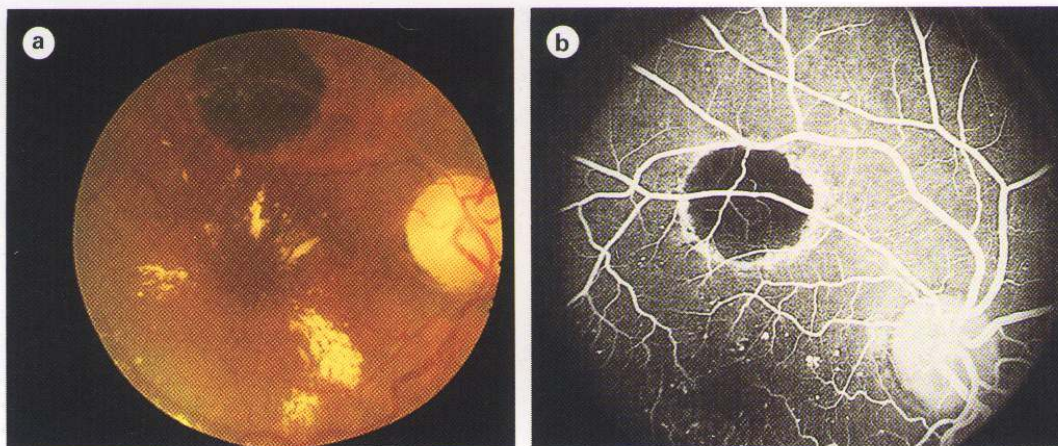


Fig. 13.35
Hypofluorescence due to blockage of background choroidal fluorescence by congenital hypertrophy of the retinal pigment epithelium and hard exudates (see text)
(Courtesy of Wilmer Institute)

2. The patient is seated in front of the camera with one arm outstretched.
3. A 'red-free' photograph is taken.
4. Between 25 and 40 mg of dye is injected intravenously.
5. Rapid serial photographs are taken initially and then subsequent photographs are taken at about 3 minutes, 10 minutes and 30 minutes.
6. Late phases yield the most useful information, because the dye remains in neovascular tissue after leaving the retinal and choroidal circulations.

If necessary, ICG angiography may be performed simultaneously with or sequentially to FA. ICG videoangiography (ICG-VA) is commonly used as a supplementary test to FA in the diagnosis and treatment of occult CNV. The two angiographic systems used in performing ICG-VA are the high-resolution digital fundus camera and the scanning laser ophthalmoscope. ICG-guided laser treatment of occult CNV is based on the detection of focal spots or plaques by the digital ICG-VA. The scanning laser ophthalmoscope is better at detecting the vascular net in the very early transit phase of the ICG-VA.

Adverse effects

These are less common than with FA. Because ICG contains 5% iodine it should not be given to patients allergic to iodine. Its use is also contraindicated in pregnancy. The most common side effects are staining of stool, nausea, vomiting, sneezing and pruritus. Less common manifestations include syncope, skin eruptions, pyrexia, backache and local skin necrosis.

The normal angiogram

1. **Early phase** (2–60 seconds) (Fig. 13.36a)
 - Hypofluorescence of the optic disc associated with poor perfusion of the watershed zone.
 - Prominent filling of choroidal arteries and early filling of choroidal veins.
 - Retinal arteries are visible but not veins.

2. **Early mid phase** (1–3 minutes) (Fig. 13.36b)
 - Filling of the watershed zone.
 - Fading of choroidal arterial filling with more prominent filling of choroidal veins.
 - Both retinal veins and arteries are visible.
3. **Late mid phase** (3–15 minutes) (Fig. 13.36c)
 - Fading of filling of choroidal vessels.
 - Diffuse hyperfluorescence as the result of diffusion of dye from the choriocapillaris.
 - Retinal vessels are still visible.
4. **Late phase** (15–30 minutes) (Fig. 13.36d)
 - Hypofluorescence of choroidal vasculature against a background of hyperfluorescence resulting from staining of extrachoroidal tissue.
 - Lack of visibility of retinal vasculature.
 - The dye may remain in neovascular tissue after it has left the choroidal and retinal circulations.

Causes of abnormal fluorescence

1. **Hyperfluorescence**
 - a. RPE 'window' defect.
 - b. Leakage from the retinal or choroidal circulations, or the optic nerve head.
 - c. Abnormal blood vessels.
2. **Hypofluorescence**
 - a. Blockage of fluorescence by pigment, blood or exudate.
 - b. Obstruction of the circulation.
 - c. Loss of vascular tissue.
 - d. RPE detachment (hyperfluorescent on FA).

Laser photocoagulation

LASER is an acronym for **L**ight **A**mplification by **S**timulated **E**mission of **R**adiation. Retinal laser photocoagulation is essentially a destructive form of therapy dependent on the absorption of light energy by ocular pigments (melanin, haemoglobin and xanthophyll) and its conversion into heat.

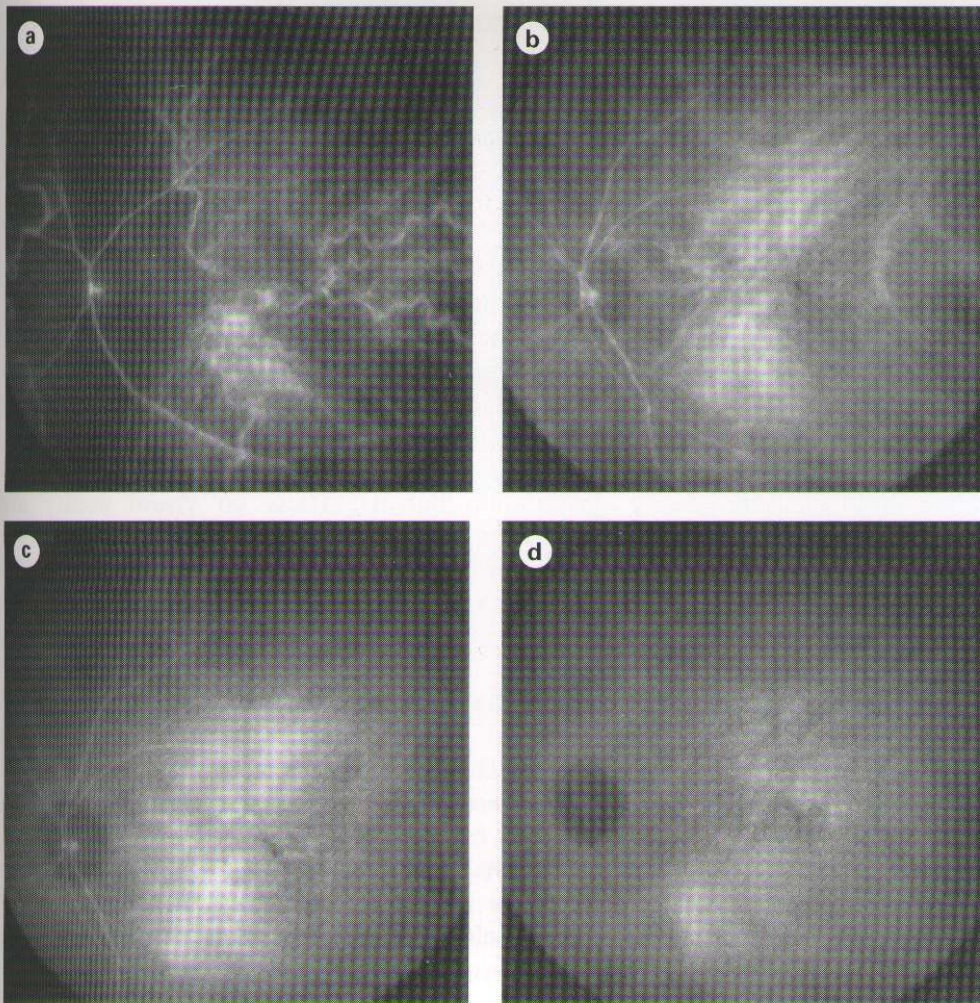


Fig. 13.36
Normal ICG angiogram (see text)

Lasers produce a collimated, coherent monochromatic beam that can deliver a large amount of energy to a small area. The purpose of laser therapy is to produce a therapeutic burn to a pre-selected area of the retina while causing minimal damage to surrounding tissue. The main indications for laser photocoagulation are the following:

- Retinal vascular diseases.
- Choroidal neovascular membranes.
- High-risk retinal breaks and predisposing peripheral retinal degenerations.
- Selected intraocular tumours.

Ocular pigments

1. **Melanin** is the most important pigment and is present in the RPE and choroid. Light absorbed by melanin in the RPE is the main source of energy in retinal photocoagulation.
2. **Haemoglobin** best absorbs argon laser energy but is only a significant source of heat when most of the laser energy is concentrated on a blood vessel.
3. **Xanthophyll** is a yellow pigment in the inner retinal layers of the macula. It becomes a heat source only when

blue-green argon laser photocoagulation is applied close to the fovea.

Wavelengths

An increasing choice of wavelengths is becoming available, each with its own theoretical advantages and disadvantages. The choice of optimum wavelength depends on the absorption spectrum of target tissue. Currently, the main lasers used for retinal photocoagulation are:

1. **Argon**, which emits coherent blue-green light of 488–515 nm. The beam consists of 70% blue and 30% green light, which can be converted to purely green by the incorporation of a filter. Blue-green wavelengths are well absorbed by all three pigments. However, blue light (488 nm) is undesirable when treating macular disease because it is absorbed by xanthophyll. Green light is absorbed well by melanin and haemoglobin but much less by xanthophyll and is therefore preferred when treatment is required close to the fovea.
2. **Krypton**, which emits yellow light at about 577 nm, is becoming increasingly popular because of its ability to directly coagulate red lesions.
3. **Diode**, which emits infrared light at 780–950 nm.

Practical aspects

1. Delivery systems

- Slit-lamp* delivery using a special contact lens is the most common method.
- Indirect ophthalmoscope* with a condensing lens may be used to treat retinopathy of prematurity and other pathology.
- Intraocular* (endolaser) photocoagulation via fibre-optic probes are used during pars plana vitrectomy.

2. The burn

- Spot size* is 50–500 μm . The spot size for focal macular treatment is smaller (50–200 μm) than that required for panretinal photocoagulation (300–500 μm). Different contact lenses have variable effects on spot size. For example, while the Goldmann lens does not significantly alter spot size, other contact lens systems and panfundoscopes may enlarge the retinal spot size by 35–50%.
- Power settings* are 0–3 W (0–3000 mW). Heavily pigmented fundi require less energy than hypopigmented fundi to acquire equivalent burns.
- Exposure times* are usually 0.01–5 seconds although diode laser photocoagulation (thermotherapy) of certain intraocular tumours requires much longer exposure times.

NB: When spot size is reduced, power remains constant but is spread over a smaller area. The energy level per unit area therefore increases. When changing to a smaller spot size the power must therefore be reduced.

Complications

- Foveal damage** may occur as a result of the following mechanisms:

- Direct burn*, which usually occurs when treating the temporal retinal periphery with the equatorial mirror.

NB: Constant reference to the fovea is essential to avoid this serious complication.

- Oedema* may occur following extensive (panretinal) photocoagulation. Fortunately it usually resolves spontaneously after a few weeks.
- Pucker* is also associated with panretinal photocoagulation but its effects on visual acuity are permanent.
- 'Spill-over' scarring* may occur months after initial treatment close to the fovea. In this condition the laser scars gradually increase in size to encroach upon the fovea.

- Choroidal haemorrhage** may occur when a very small (i.e. 50 μm) but high-energy burn ruptures Bruch membrane. This may also lead to CNV (Fig. 13.37c) and subsequent secondary retinal fibrovascular proliferation (Fig. 13.37a, b and d).

- Contraction of fibrous tissue** is a potentially serious complication which may occur when laser burns are applied too closely. Special care should be taken when treating neovascularization associated with large areas of fibrous tissue, because the energy generated may

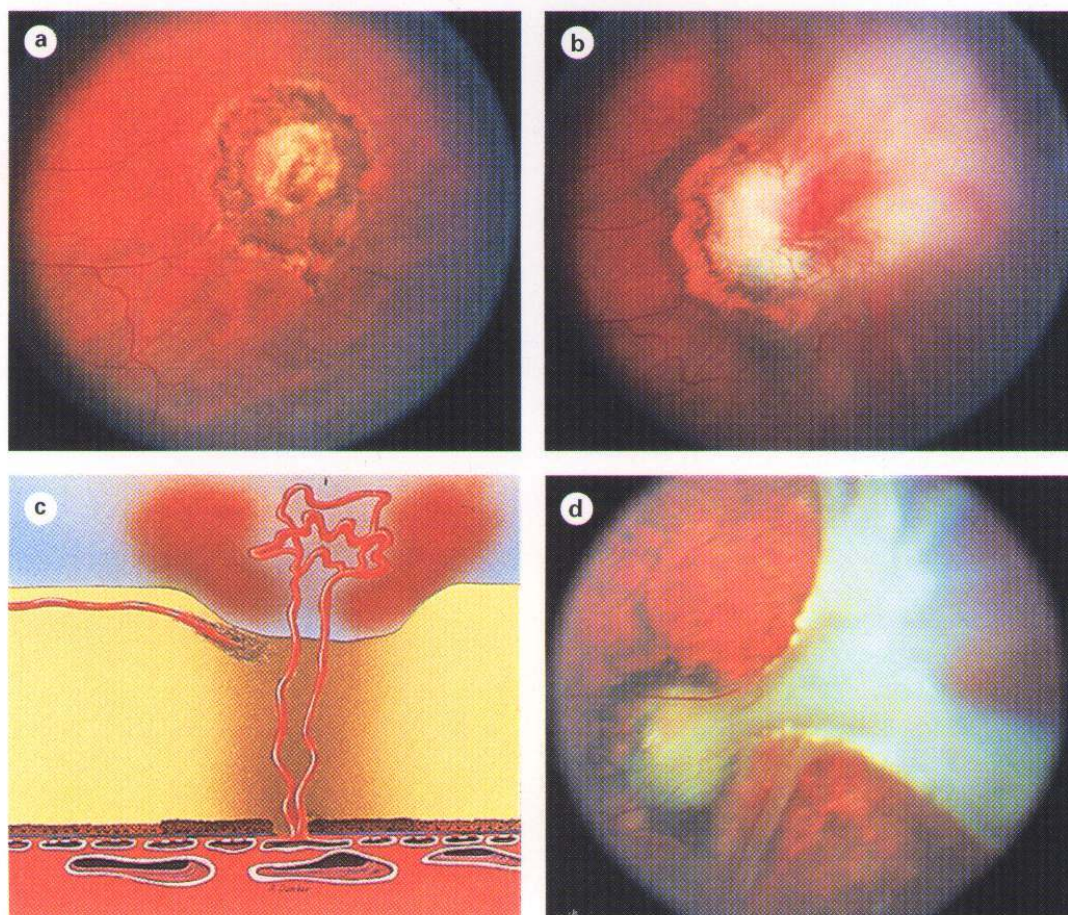


Fig. 13.37
Choroidal neovascularization and secondary fibrous proliferation following inappropriate argon laser photocoagulation (see text) (Courtesy of Wilmer Institute)

induce contraction and subsequent tractional retinal detachment.

4. **Effects on visual function** from extensive retinal photocoagulation include night blindness, altered colour and light brightness appreciation, and constriction of visual fields.
5. **Other complications**, which are rare, include iris burns, choroidal effusion and vitreous haemorrhage.

Age-related macular degeneration

Introduction

Definition

Age-related macular degeneration (AMD) is a disease of the macular area, most often clinically apparent after 50 years of age, which has early and late characteristics:

1. Early

- Discrete yellow spots at the macula (drusen).
- Hyperpigmentation of the RPE.
- Sharply demarcated areas of RPE depigmentation.

2. Late

- Geographic atrophy of the RPE with visible underlying choroidal vessels.
- PED with or without neurosensory detachment.
- Subretinal or sub-RPE neovascularization.
- Fibroglial scar tissue, haemorrhage and exudates.

Prevalence

AMD is the most common cause of irreversible visual loss in the western world in individuals over 50 years of age. The prevalence of severe visual loss increases with age. In the USA, at least 10% of individuals between the ages of 65 and 75 years have lost some central vision as a result of AMD. Among those over 75, 30% are affected to some degree. End-stage (blinding) AMD is found in about 1.7% of all individuals aged over 50 years and in about 18% in those over 85 years. AMD may take two patterns:

1. **Atrophic** (dry, non-exudative) AMD, by far the most common, is a slowly progressive disease characterized by drusen and geographic atrophy of the RPE.
2. **Exudative** (wet, neovascular) AMD, less common but devastating, is characterized by CNV and eventual subretinal scarring.

Risk factors

AMD is most prevalent in Caucasians. Genetic and environmental factors appear to modify the risk of visual loss although the relative importance of these is unclear. Cigarette smoking is the only modifiable risk factor.

Drusen

Histopathology

Loss of central vision in AMD is the result of changes that occur in response to deposition of abnormal material in Bruch membrane. This material is derived from the RPE, and its accumulation is thought to result from failure to clear the debris discharged into this region. Drusen consist of discrete deposits of this abnormal material located between the basal lamina of the RPE and the inner collagenous layer of Bruch membrane (Fig. 13.38). The abnormal material also accumulates diffusely throughout Bruch membrane. Thickening of the inner part of Bruch membrane is compounded by excessive production of basement membrane-like material by the RPE. It has been postulated that the lipid content of drusen may be a determinant for subsequent behaviour.

Signs

Drusen appear as yellow excrescences beneath the RPE, distributed symmetrically at both posterior poles. They may vary in number, size, shape, degree of elevation and extent of associated RPE changes. In some patients, drusen may be confined to the region of the fovea, whereas in others the deposits encircle but spare the fovea itself. Drusen are rarely clinically visible before the age of 45 years; they are not uncommon between the ages of 45 and 60 years and almost universal thereafter. With advancing age they increase in size and number.

1. **Hard drusen** are small, round, discrete, yellow-white spots associated with focal dysfunction of the RPE and are usually innocuous (Fig. 13.39).
2. **Soft drusen** are larger, and have indistinct margins (Fig. 13.40). They may slowly enlarge and coalesce to form a solid 'drusenoid' detachment of the RPE (Fig. 13.41a) best demonstrated on FA (Fig. 13.41b). The occurrence of soft coalescent macular drusen is a common precursor of atrophic and exudative AMD. In some cases drusen may undergo secondary dystrophic calcification and acquire a glistening appearance (Fig. 13.42).

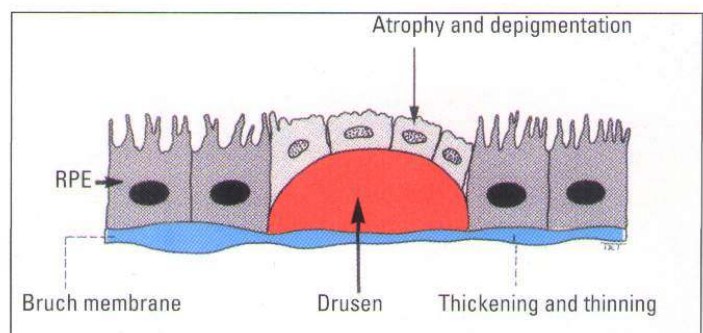


Fig. 13.38
Location of drusen and changes in Bruch membrane

Fluorescein angiography

The findings on FA depend on the state of the overlying RPE and the degree of staining of drusen.

1. **Hyperfluorescence** is caused by both a window defect due to atrophy of the overlying RPE and late staining. It has been postulated that hyperfluorescent drusen are hydrophilic (low lipid content) and predispose to CNV.

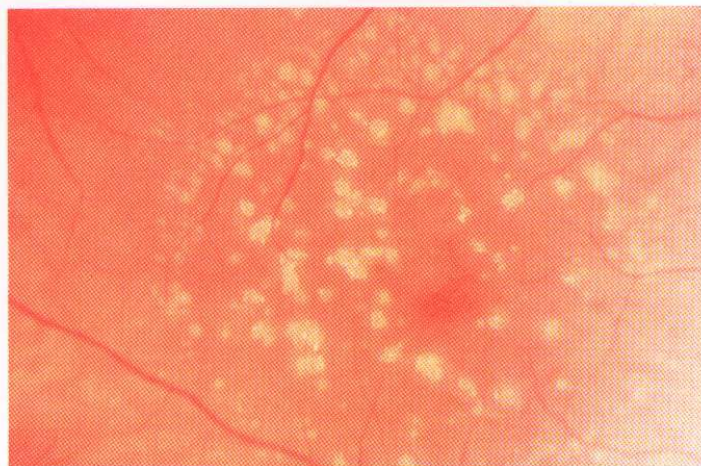


Fig. 13.39
Hard drusen

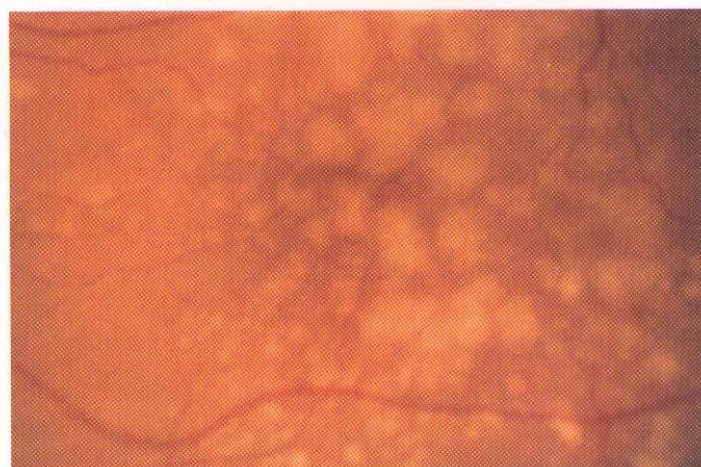


Fig. 13.40
Soft drusen

2. **Hypofluorescent** drusen are hydrophobic (high lipid content) and, if large and confluent, predispose to subsequent detachment of the RPE. A prolonged filling phase of the choroid may indicate diffuse thickening of Bruch membrane.

Differential diagnosis

1. **Familial dominant drusen (Doyle honeycomb dystrophy)** is an uncommon condition in which drusen appear during the second to third decades of life (see Chapter 15).
2. **Hard exudates** in diabetic retinopathy may, on cursory examination, be confused with drusen. However, unlike drusen, they lie intraretinally, are arranged in rings or clumps and are associated with vascular changes such as microaneurysms and haemorrhages (see Chapter 14).
3. **Type 2 membranoproliferative glomerulonephritis** is a rare disease characterized by haematuria, proteinuria and renal failure. Affected patients manifest bilateral, symmetrical, diffuse yellow, drusen-like lesions at the posterior pole.
4. **Other causes** of retinal flecks include hereditary conditions such as fundus flavimaculatus, Stargardt

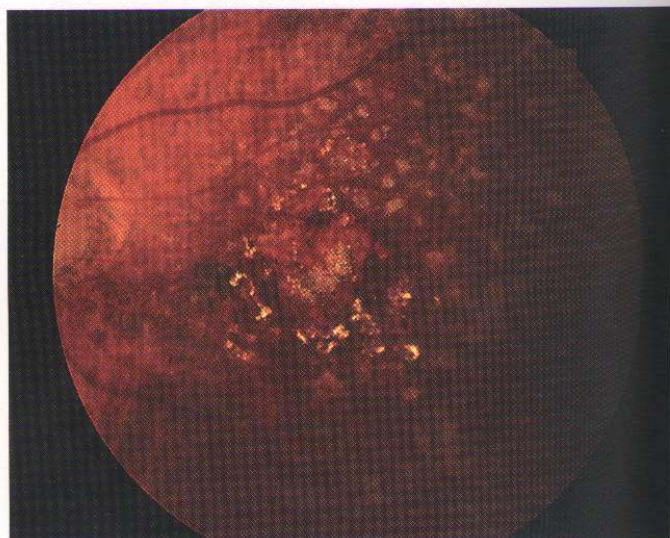

Fig. 13.42
Calcified drusen

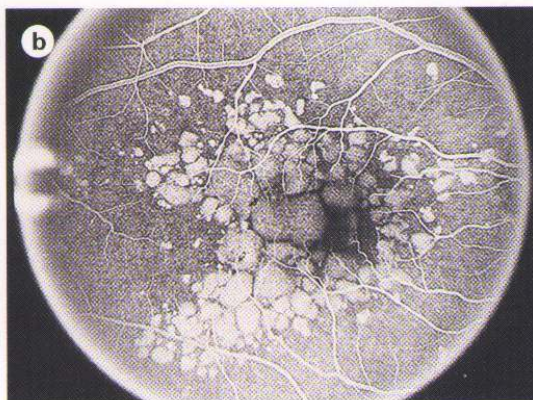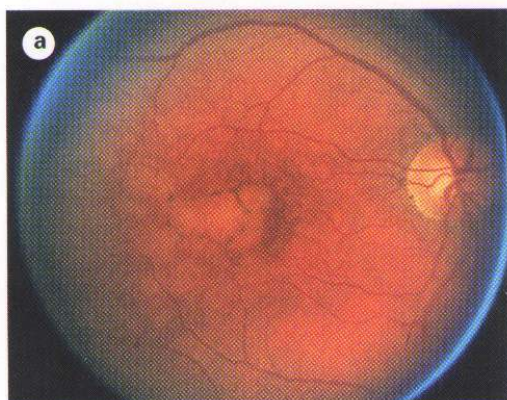


Fig. 13.41
Drusenoid PED (see text)
(Courtesy of Wilmer Institute)

disease, benign flecked retina, North Carolina macular dystrophy and Alport syndrome (see Chapter 15). In all of these, the fundus lesions develop at a much earlier age than drusen.

Drusen and AMD

Although many patients with drusen maintain normal vision throughout life, a significant number of elderly patients develop AMD (Fig. 13.43). The exact role of drusen in the pathogenesis of AMD is still unclear, although their chemical composition may be relevant. Features associated with an increased risk of subsequent visual loss include large soft and/or confluent drusen, and focal hyperpigmentation of the RPE, particularly if the other eye has already developed AMD.

Prophylactic treatment

1. **Low-energy argon laser photocoagulation** reduces the number and extent of drusen and may also induce a

modest improvement of visual function. Although side effects are uncommon, there is a suggestion that such treatment may predispose to CNV. Prophylactic treatment is therefore currently not recommended.

2. **Supplemental antioxidants** (vitamin C, vitamin E and beta-carotene) and zinc may protect eyes with high-risk drusen from developing AMD.

Atrophic age-related macular degeneration

Atrophic AMD is caused by slowly progressive atrophy of the photoreceptors, RPE and choriocapillaris (Fig. 13.44b and d) although occasionally it may follow subsidence of an RPE detachment (see later).

1. **Presentation** is with a gradual impairment of vision over months or years. Both eyes are usually affected but often asymmetrically.

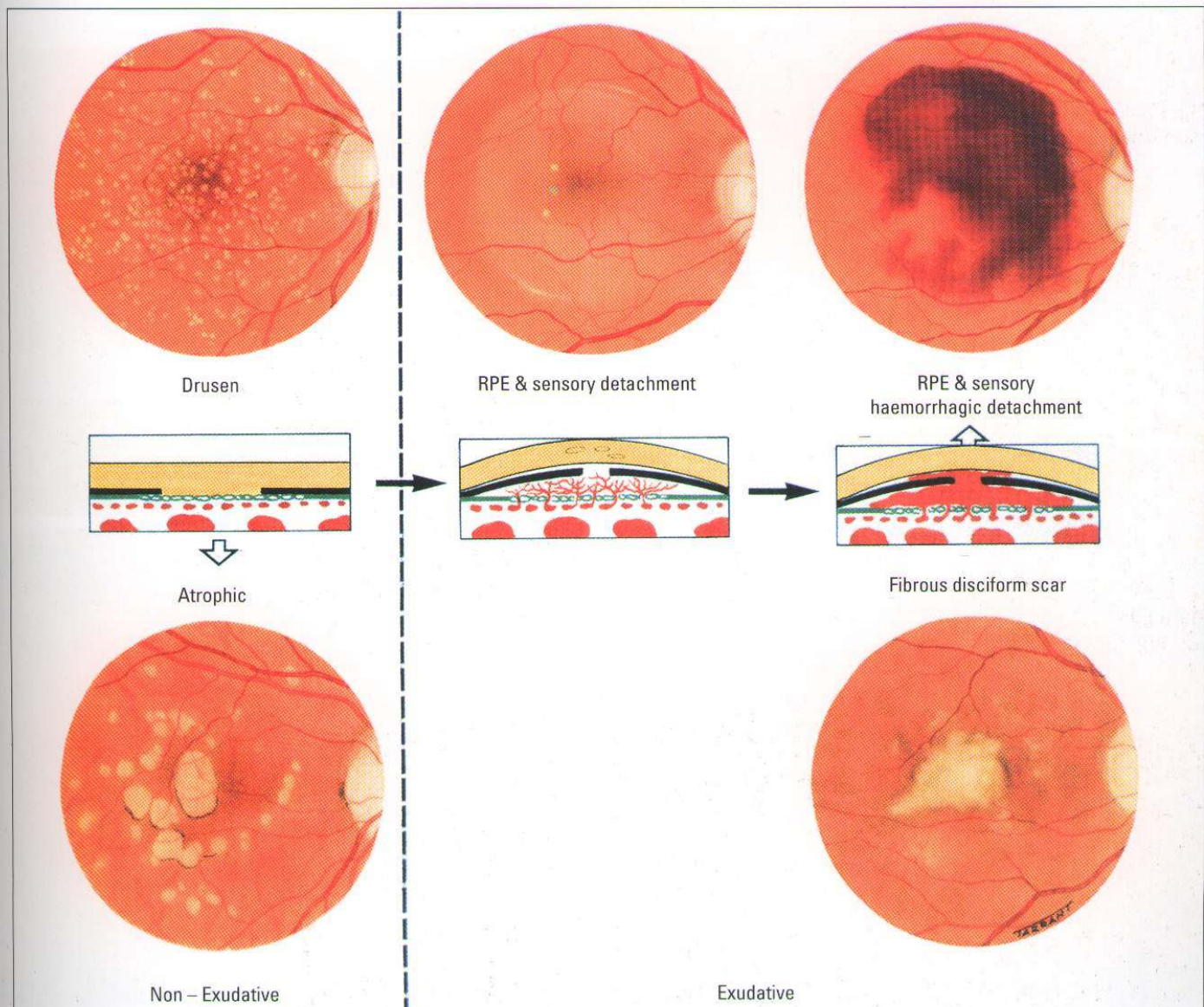


Fig. 13.43
Association between drusen and AMD (see text)

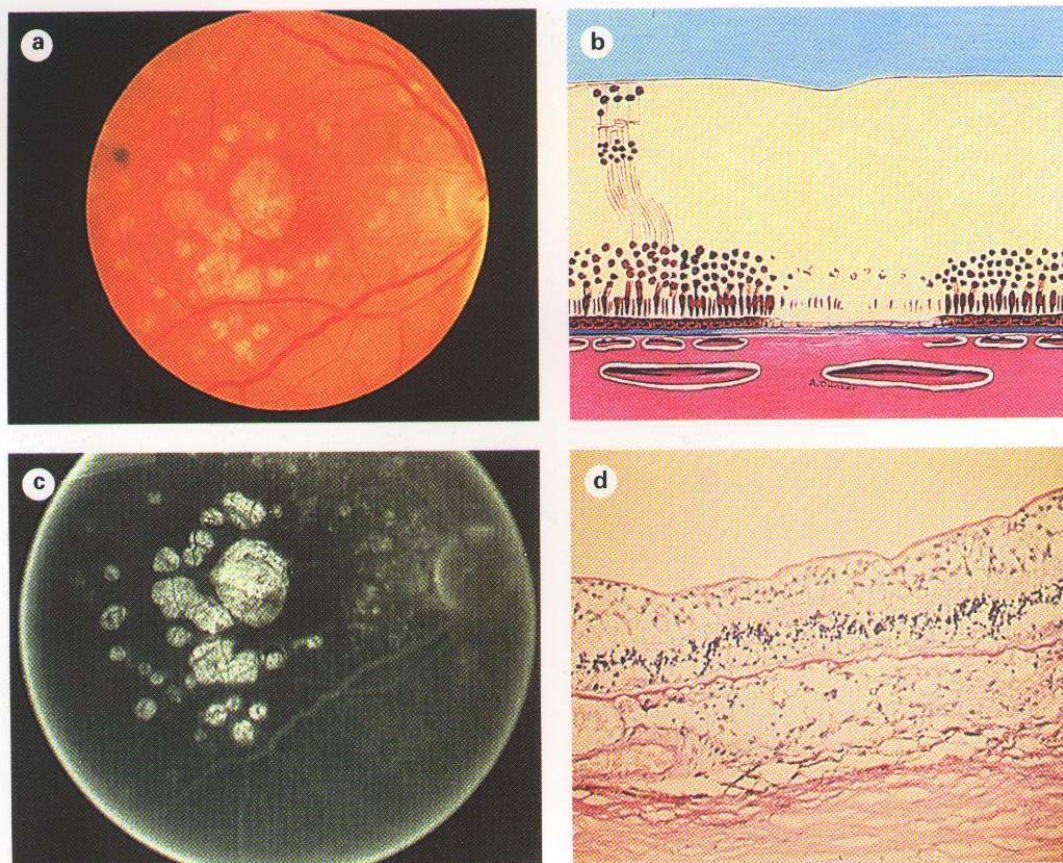


Fig. 13.44
Atrophic AMD (see text)
(Courtesy of Wilmer Institute)

2. Signs (in chronological order)

- Focal hyperpigmentation or atrophy of the RPE in association with macular drusen (Fig. 13.45).
- Sharply circumscribed, circular areas of RPE atrophy associated with variable loss of the choriocapillaris (Fig. 13.46).
- Enlargement of the atrophic areas within which the larger choroidal vessels may become visible and pre-existing drusen disappear (geographic atrophy)

(Fig. 13.47). Visual acuity is severely impaired if the fovea is involved.

3. FA shows hyperfluorescence due to unmasking of background choroidal fluorescence (see Fig. 13.44c) which may be more extensive than that apparent clinically, if the underlying choriocapillaris is still intact.

4. Treatment is not possible although low-vision aids (Fig. 13.48) may be useful in many patients.

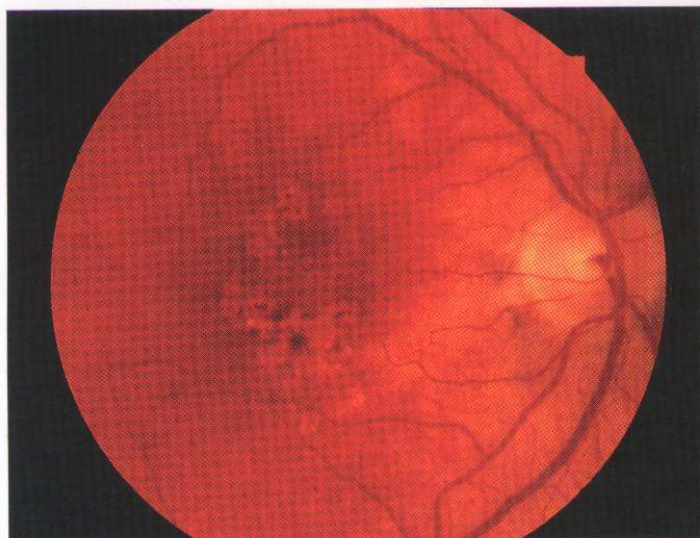


Fig. 13.45
Diffuse RPE changes and drusen in early atrophic AMD

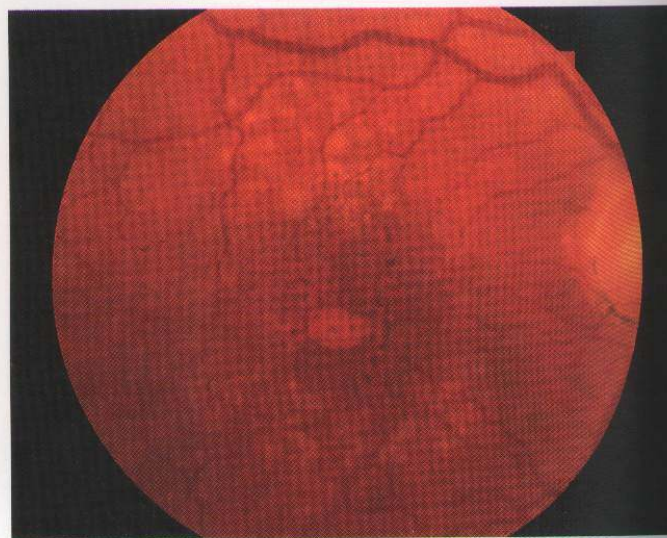


Fig. 13.46
Focal RPE atrophy and drusen in atrophic AMD

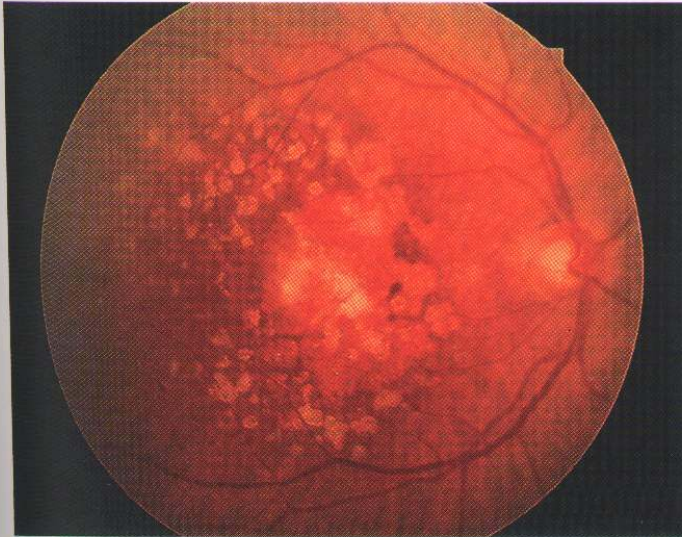


Fig. 13.47
Geographic atrophy




Fig. 13.48
Patient trying out a low vision aid

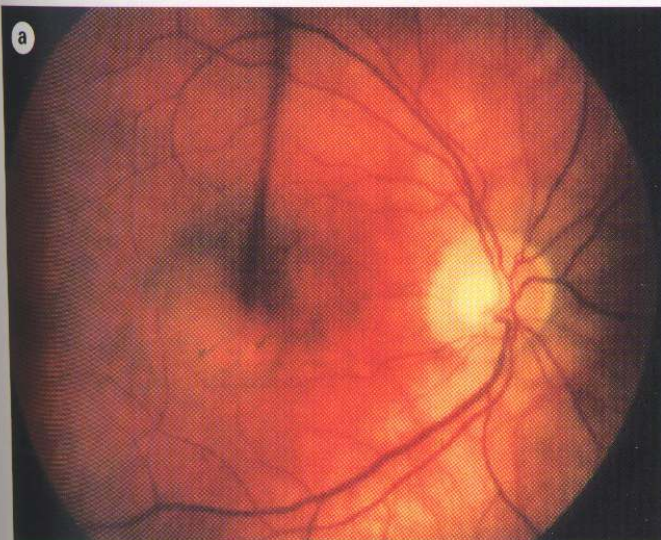
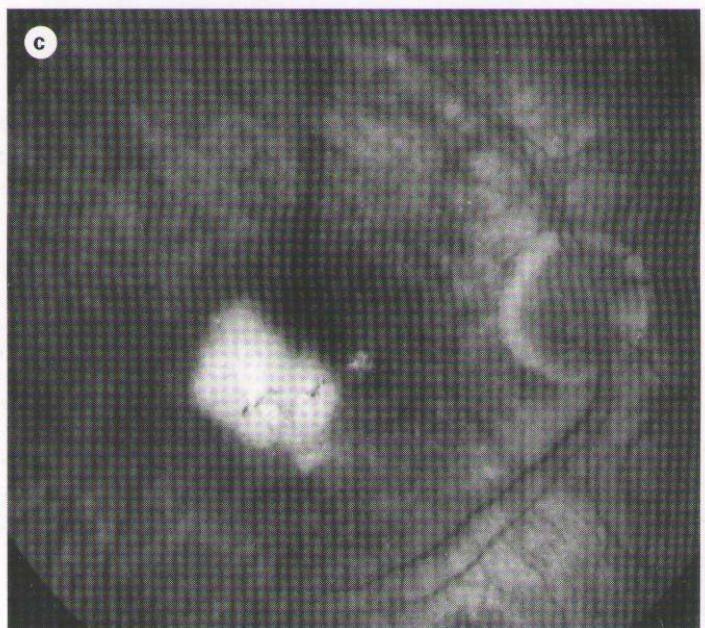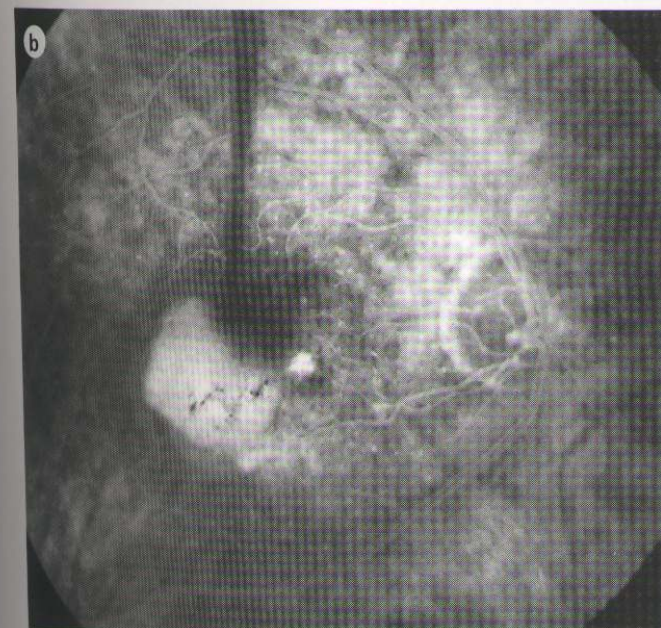


Fig. 13.49
(a) PED; (b and c) FA (see text) (Courtesy of S. Milewski)



Retinal pigment epithelial detachment

PED is thought to be caused by reduction of hydraulic conductivity of the thickened Bruch membrane, thus impeding the movement of fluid from the RPE towards the choroid.

Diagnosis

1. **Presentation** is with unilateral metamorphopsia and impairment of central vision.
2. **Signs**
 - Sharply circumscribed, dome-shaped elevation at the posterior pole of varying size (Fig. 13.49a).
 - The sub-RPE fluid is usually clear but may be turbid.
3. **FA**
 - The venous phase demonstrates a well-demarcated area of hyperfluorescence due to pooling of dye under the detachment (Fig. 13.49b).
 - The late phase shows increased hyperfluorescence but no change in size (Fig. 13.49c).
4. **ICG** shows an oval area of hypofluorescence with a faint ring of surrounding hyperfluorescence (Fig. 13.50a and b).

NB: Laser photocoagulation should not be performed for PED.

Course

This is variable and may follow one of the following patterns:

1. **Spontaneous resolution** without residua, particularly in younger patients.
2. **Geographic atrophy** may develop following spontaneous resolution in a minority of patients.
3. **Detachment of the sensory retina** may occur due to breakdown of the outer blood-retinal barrier, allowing passage of fluid into the subretinal space. Because of the relatively loose adhesion between the RPE and sensory retina, the subretinal fluid spreads more widely and is less well defined than in a pure PED.
4. **Occult CNV** may develop or have been present, undetected, from the start (*see below*).
5. **RPE tear formation** (*see next*).

Retinal pigment epithelial tear

A tear of the RPE may occur at the junction of attached and detached RPE if tangential stress becomes sufficient to rupture the detached tissue. Tears may occur spontaneously or following laser photocoagulation of CNV in eyes with PED.

1. **Presentation** is with sudden worsening of central vision.

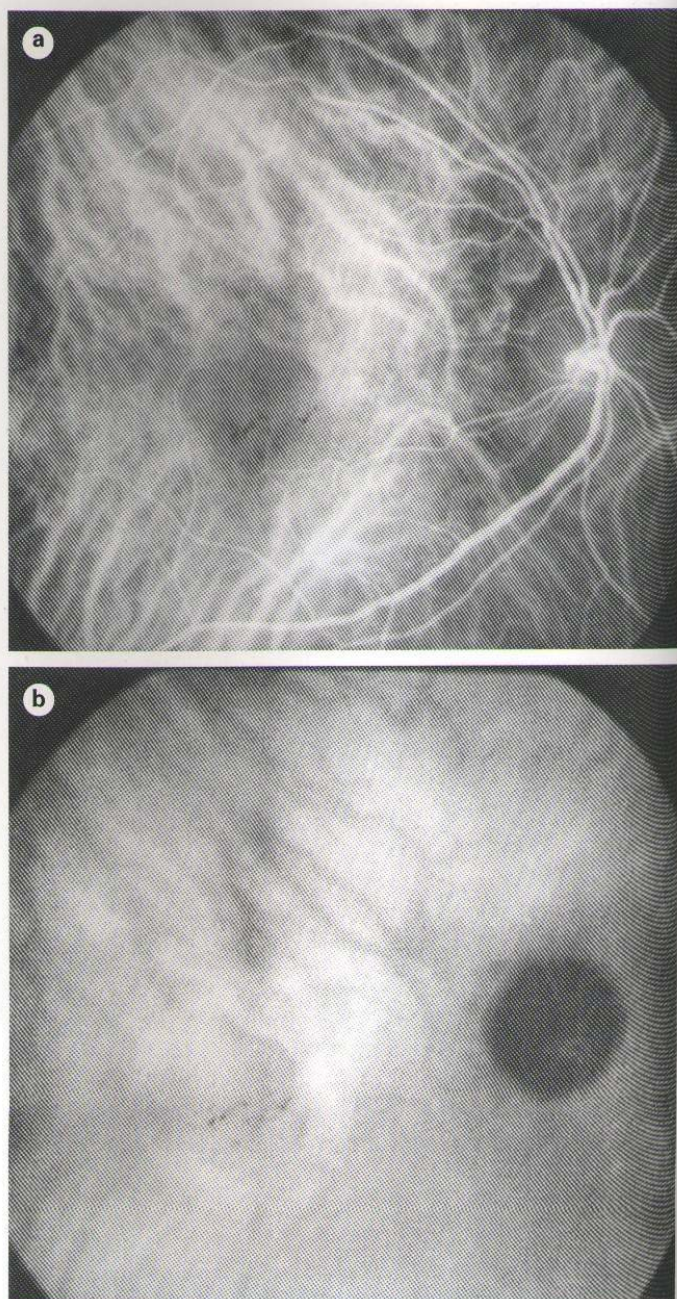
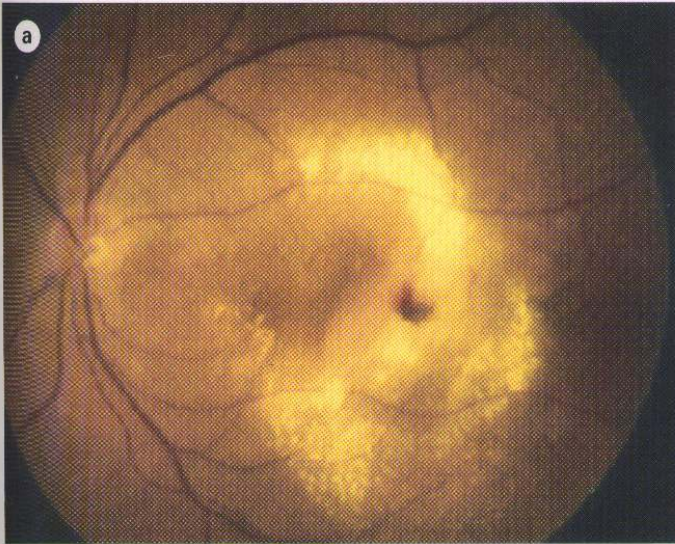
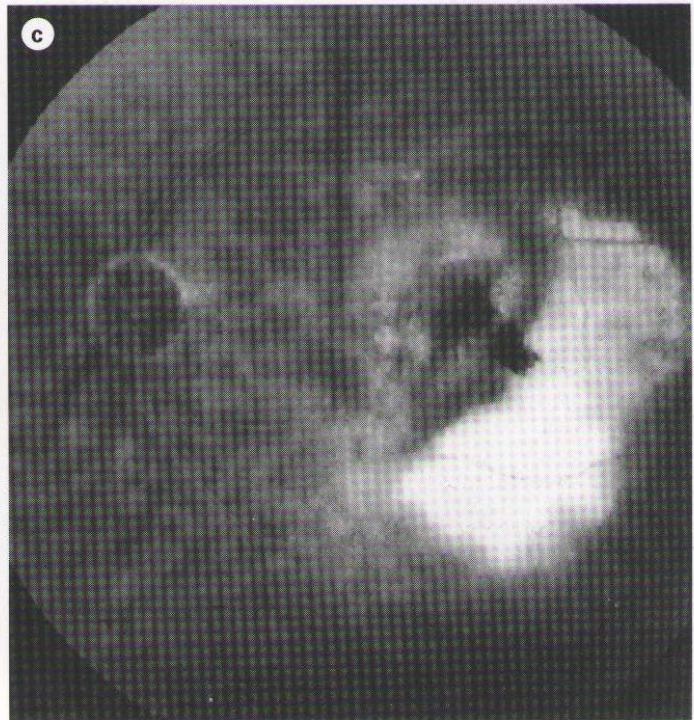
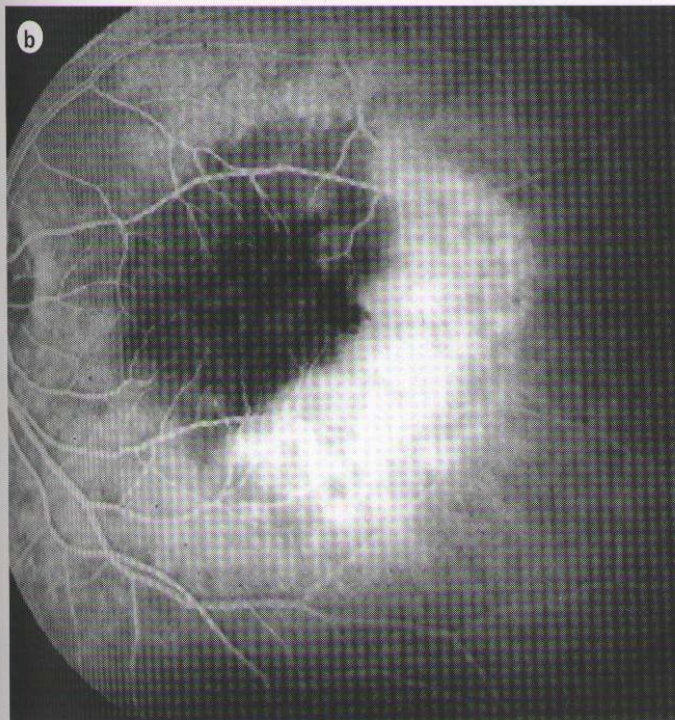


Fig. 13.50
ICG of PED (*see text*) (Courtesy of S. Milewski)

2. **Signs.** Crescent-shaped RPE dehiscence at the edge of a prior serous detachment with a retracted and folded flap (Fig. 13.51a).
3. **FA** shows hypofluorescence over the flap due to the folded over and thickened RPE, with adjacent hyperfluorescence due to the exposed choriocapillaris (Fig. 13.51b and c).
4. **Prognosis** of subfoveal tears is poor. Detachments of the RPE progressing to tears have an especially poor prognosis and are at particular risk of developing visual loss in the fellow eye. A minority of eyes maintain good visual acuity despite RPE tears, particularly if the fovea is spared.

**Fig. 13.51**

(a) Pigment epithelial rip; (b and c) FA (see text) (Courtesy of S. Milewski)



Exudative age-related macular degeneration

Pathogenesis

Exudative AMD is caused by CNV originating from the choriocapillaris which grows through defects in Bruch membrane. CNV may remain confined to the sub-RPE space (type 1) or subsequently extend into the subretinal space (type 2). CNV may precede or follow PED, although these two events are probably not directly related.

Clinical features

- 1. Presentation** is with metamorphopsia and blurring of central vision due to leakage of fluid from the CNV. At this stage argon laser treatment may be beneficial.
- 2. Signs.** Many membranes cannot be identified ophthalmoscopically.

- Sub-RPE (type 1) CNV may occasionally be detected clinically as a grey-green or pinkish-yellow, slightly elevated lesion (Fig. 13.52).
- Subretinal (type 2) CNV may occasionally form a subretinal halo or pigmented plaque.
- The most frequent signs are caused by leakage from CNV resulting in serous retinal elevation, haemorrhage and subretinal hard exudates (Fig. 13.53).

Fluorescein angiography

FA is important for the detection and precise localization of CNV in relation to the centre of the foveal avascular zone (FAZ).

- 1. Classic CNV** is a well-defined membrane which fills with dye in a 'lacy' pattern during the very early phase of dye transit (Fig. 13.54a), fluoresces brightly during peak dye transit (Fig. 13.54b), and then leaks into the subretinal space and around the CNV within 1–2 minutes. The fibrous

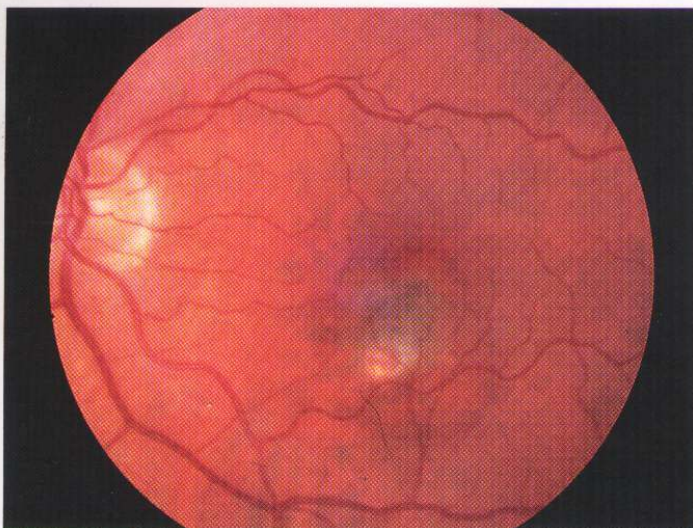


Fig. 13.52
Type 1 CNV below the fovea

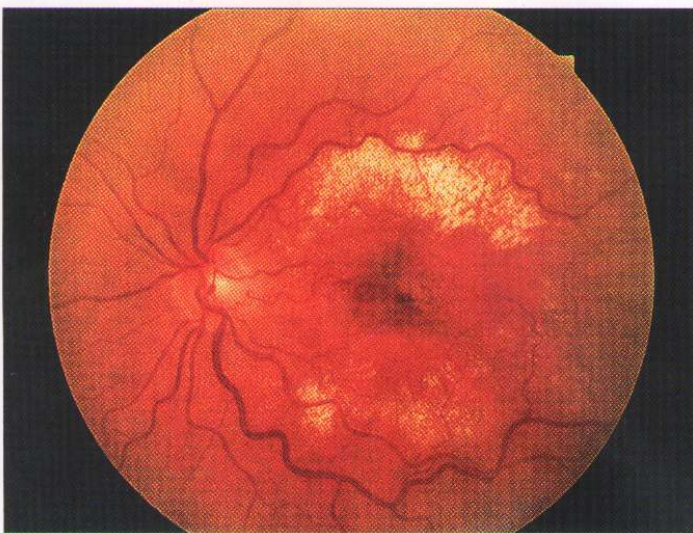


Fig. 13.53
Hard exudates and haemorrhage associated with CNV

tissue within the CNV then stains with dye with late hyperfluorescence (Fig. 13.54c). Classic CNV is classified according to its relation to the centre of FAZ as follows:

- a. **Extrafoveal** in which the CNV is more than 200 μm from the centre of the FAZ.
 - b. **Subfoveal** in which the centre of the FAZ is involved either by extension from an extrafoveal area or by originating directly under the centre of the fovea. About 70% of CNV extend subfoveally within 1 year. The visual prognosis is very poor.
 - c. **Juxtafoveal** in which the CNV is closer than 200 μm from the centre of the FAZ but does not involve it.
2. **Occult CNV** is a poorly defined membrane which has less precise features on the early frames but gives rise to late leakage.
 3. **Fibrovascular PED** is a combination of CNV and PED. The CNV fluoresces more brightly (hot spot) than the detachment (Fig. 13.55a–c). In other cases, the CNV may be obscured by blood (see Fig. 13.57b) or turbid fluid.

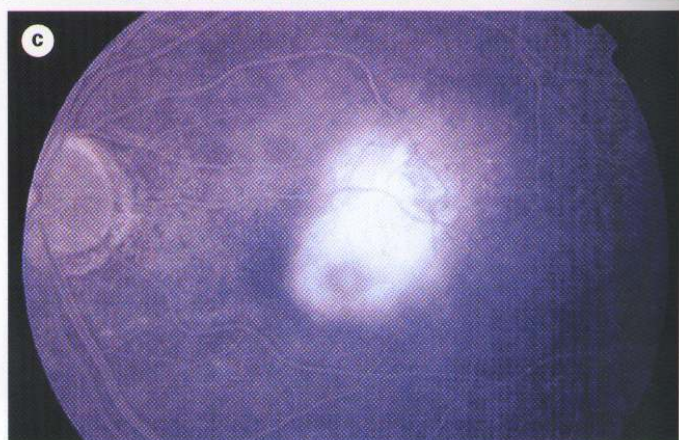
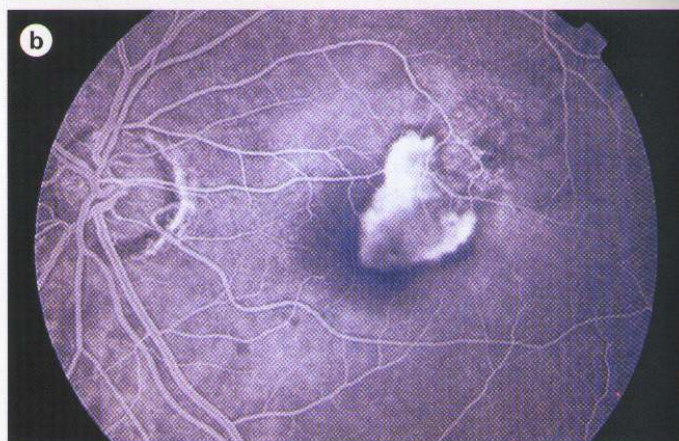
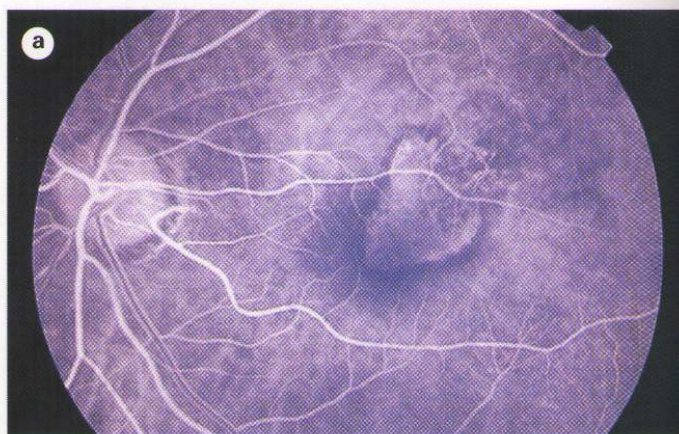
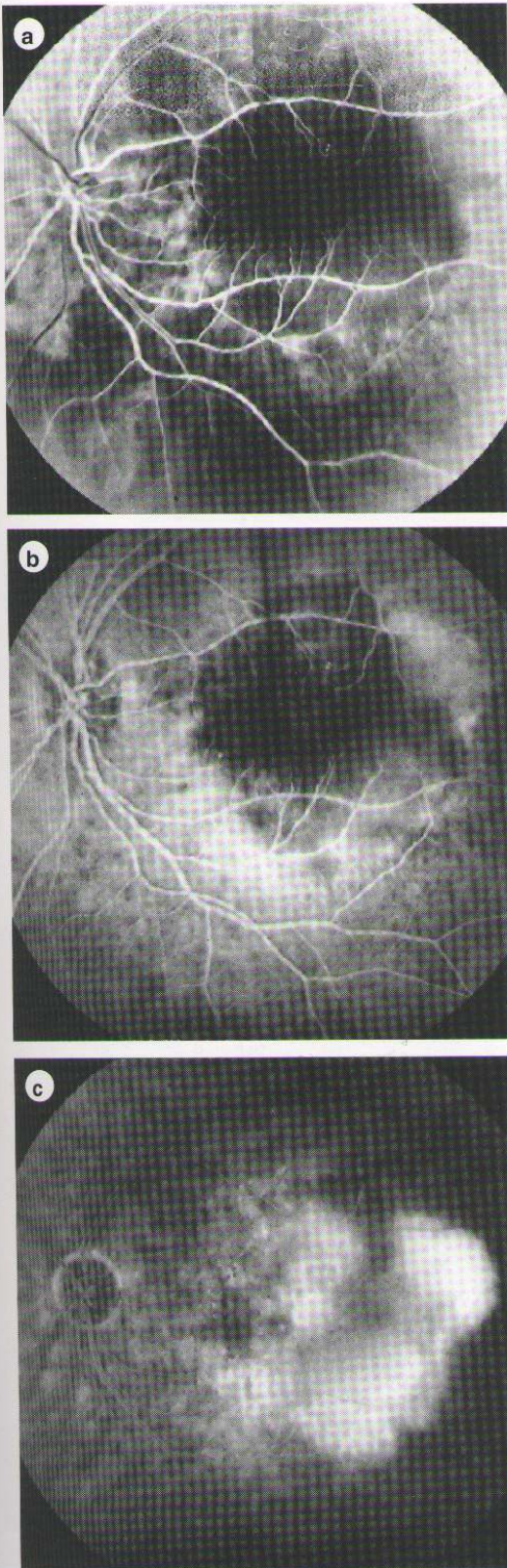


Fig. 13.54
FA of classic CNV (Courtesy of S. Milewski)

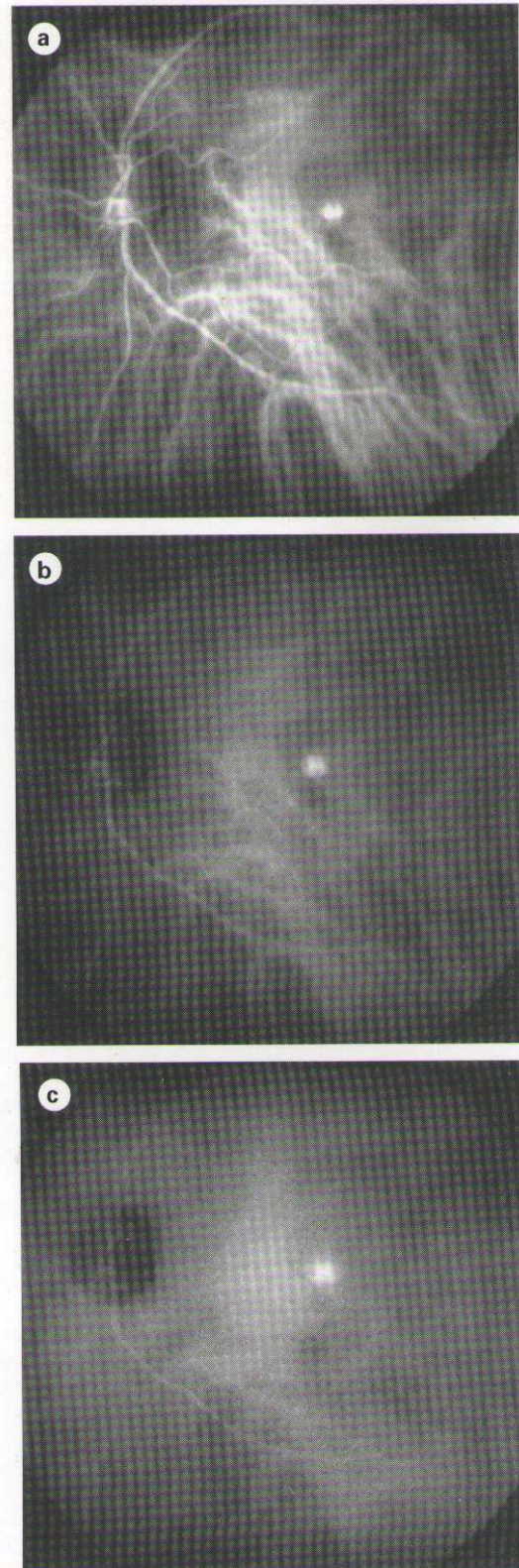
Indocyanine green angiography

ICG may be superior to FA under certain circumstances. The longer, near-infrared wavelengths can penetrate the RPE and choroid, and are less absorbed by haemoglobin. These properties allow greater transmission of ICG fluorescence than that of fluorescein and are of particular value in the following circumstances:

- Occult or poorly defined CNV.
- Distinguishing serous from vascularized portions of a fibrovascular PED (Fig. 13.56).
- CNV associated with overlying haemorrhage, pigment or exudate. For example, Fig. 13.57a shows haemorrhage

**Fig. 13.55**

FA of fibrovascular PED. Focal hyperfluorescence superotemporal to the fovea corresponds to juxtafoveal CNV; a larger area of hyperfluorescence lateral to the fovea corresponds to PED (Courtesy of S. Milewski)

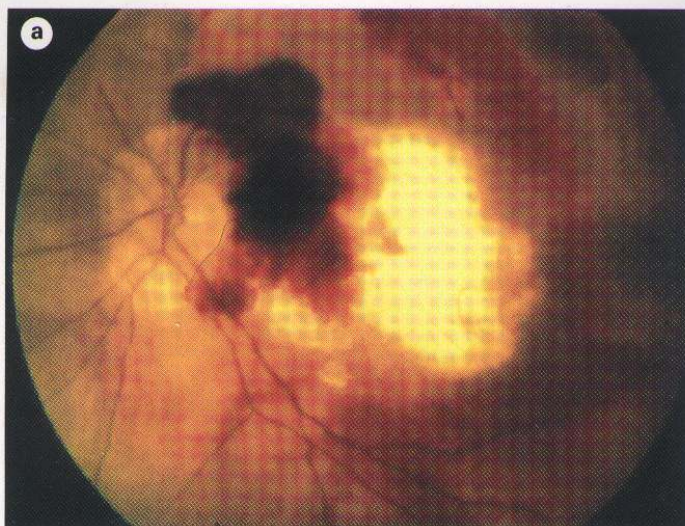
**Fig. 13.56**

ICG of a fibrovascular PED showing hypofluorescence of the detachment associated with a focal area of hyperfluorescence ('hot spot') corresponding to CNV (Courtesy of S. Milewski)

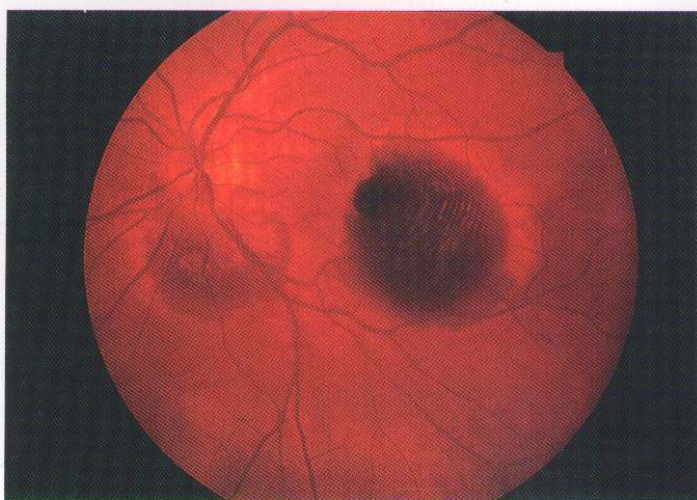
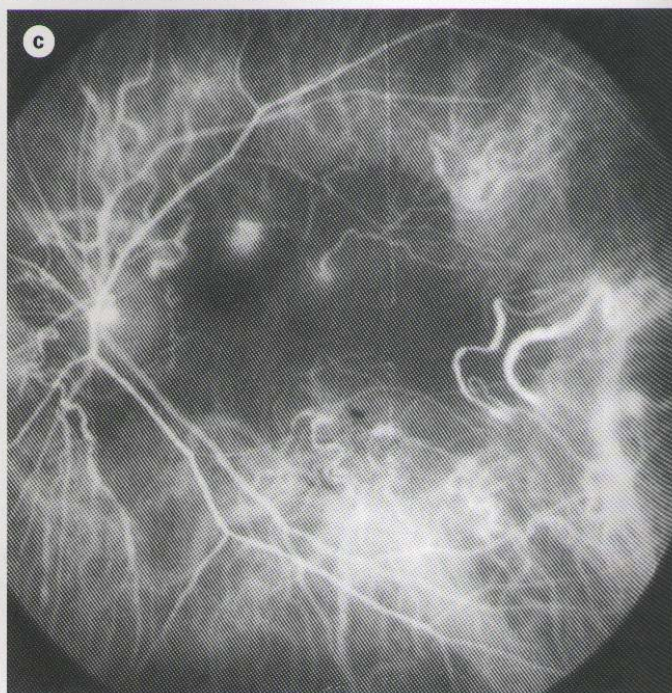
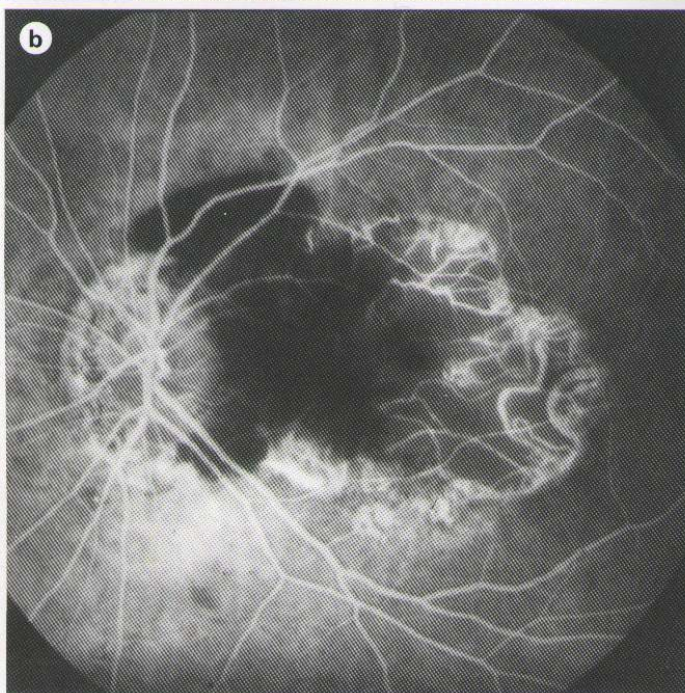
temporal to the disc and an atrophic macular scar. FA (Fig. 13.57b) shows hypofluorescence corresponding to the haemorrhage but no focal leak suggestive of

CNV. ICG, however, shows a 'hot spot' due to CNV under the haemorrhage superotemporal to the disc (Fig. 13.57c).

- Recurrent CNV adjacent to an old photocoagulation scar.

**Fig. 13.57**

(a) Haemorrhage and atrophy in AMD; (b) FA shows hypofluorescence corresponding to the haemorrhage; (c) ICG shows a 'hot spot' associated with CNV superotemporal to the disc (Courtesy of S. Milewski)

**Fig. 13.58**

Haemorrhagic pigment epithelial detachment in exudative AMD

Course

The course of untreated CNV is often relentless and the prognosis very poor. The following complications may ensue:

1. **Haemorrhagic PED** caused by rupture of blood vessels within the CNV. Initially, the blood is confined to the sub-RPE space and appears as a dark elevated mound (Fig. 13.58). The haemorrhage may then break into the subretinal space and assume a more diffuse outline and a lighter red colour which may surround or be adjacent to the PED (Fig. 13.59).
2. **Vitreous haemorrhage** may rarely occur when blood under a sensory haemorrhagic detachment breaks through into the vitreous cavity (Fig. 13.60).
3. **Subretinal (disciform) scarring** follows the haemorrhagic episode in which there is gradual organization of the blood, and further ingrowth of new vessels from the choroid (Fig. 13.61). Eventually, a fibrous disciform scar at the fovea causes permanent loss of central vision (Fig. 13.62).

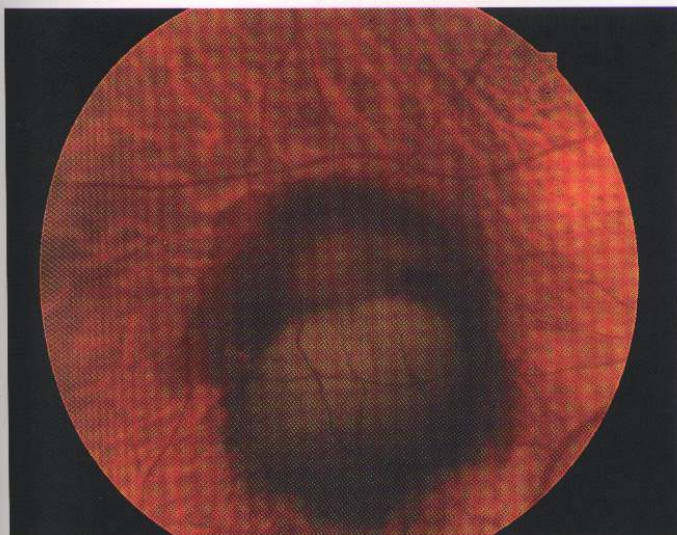


Fig. 13.59
Haemorrhagic pigment epithelial detachment with adjacent subretinal haemorrhage in exudative AMD

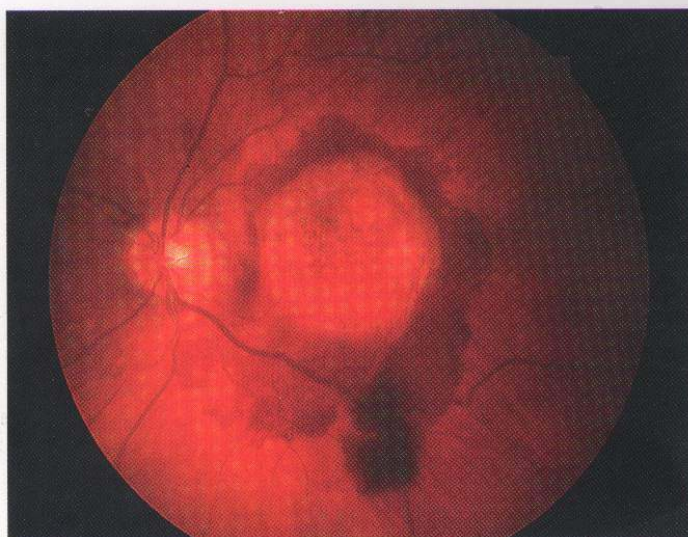


Fig. 13.61
Subretinal scarring surrounded by haemorrhage in exudative AMD

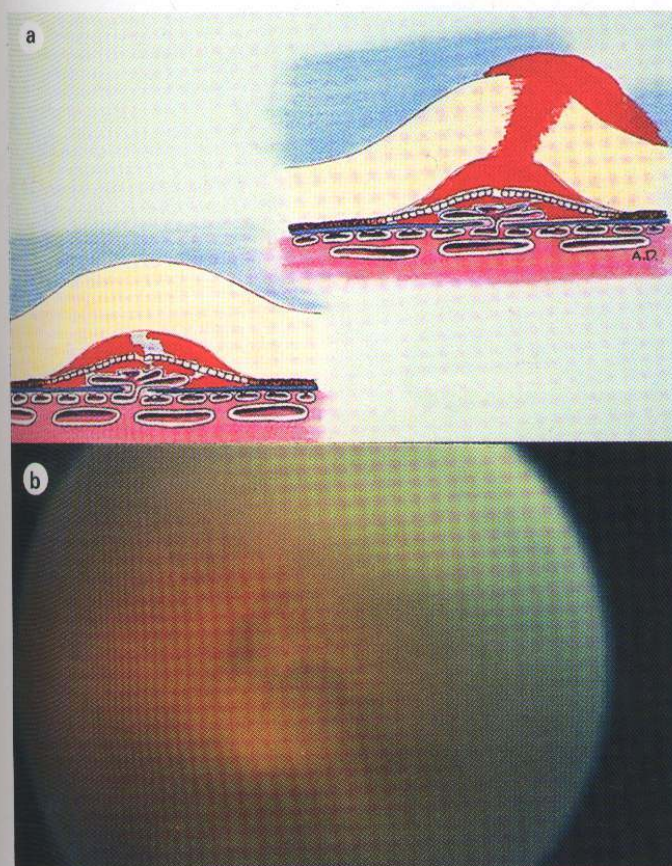


Fig. 13.60
Vitreous haemorrhage in exudative AMD (Courtesy of Wilmer Institute)

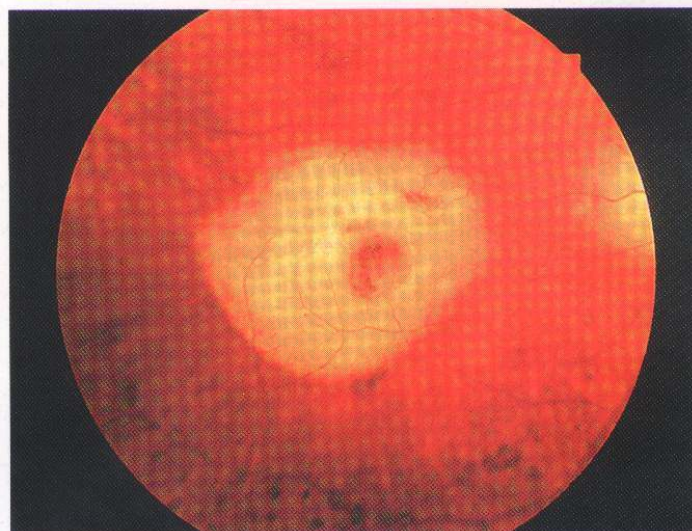


Fig. 13.62
Fibrous disciform scar in exudative AMD

Argon laser photocoagulation

Treatment of CNV reduces the risk of severe visual loss in selected cases. The aim is to destroy the CNV, while avoiding damage to the foveola. Because a lesion is more likely to be treatable if detected early, prompt identification with the daily use of the Amsler grid in patients at risk is essential.

- 1. Indications.** Extrafoveal or juxtafoveal CNV with well-defined margins (i.e. classic membranes) (Fig. 13.65).
- 2. Contraindications**

a. Poorly defined CNV, because the membrane either is occult or obscured by blood and/or serous RPE detachment. In these cases, treatment, if attempted, is often incomplete because the extent of the CNV cannot be accurately determined.

4. Massive exudation, both intra- and subretinal, may develop in some eyes with disciform scars as a result of chronic leakage from the CNV (Fig. 13.63). If severe, subretinal fluid may spread beyond the macula and destroy peripheral vision (Fig. 13.64).

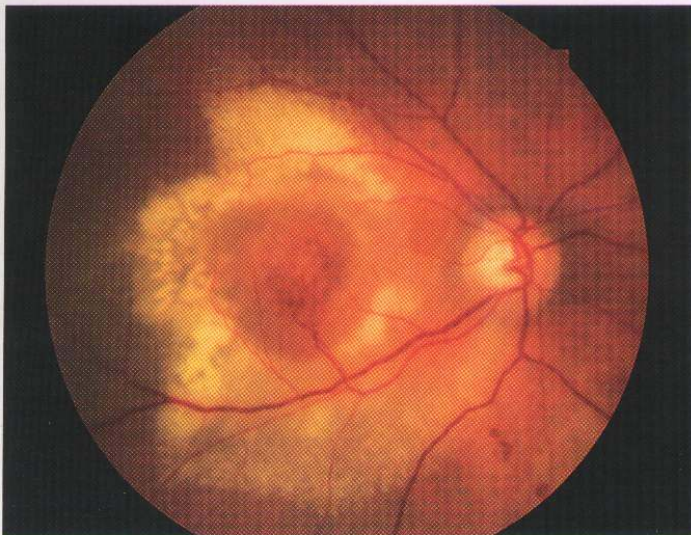


Fig. 13.63
Massive subretinal exudation in exudative AMD

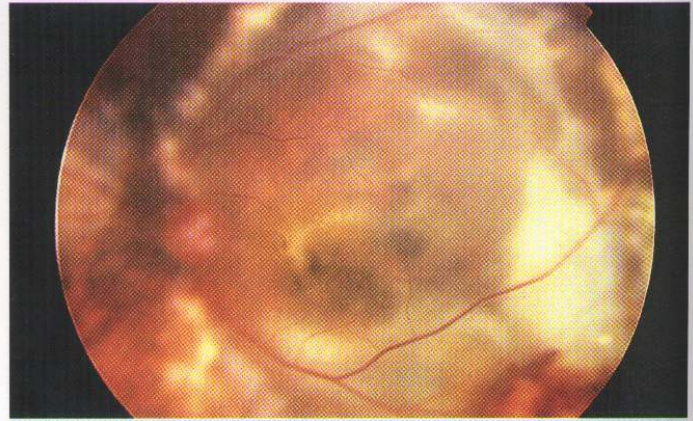


Fig. 13.64
Exudative retinal detachment in exudative AMD

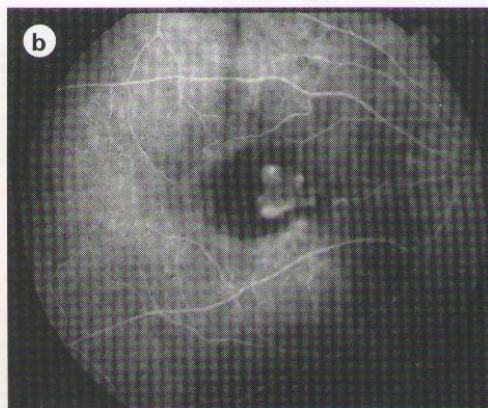
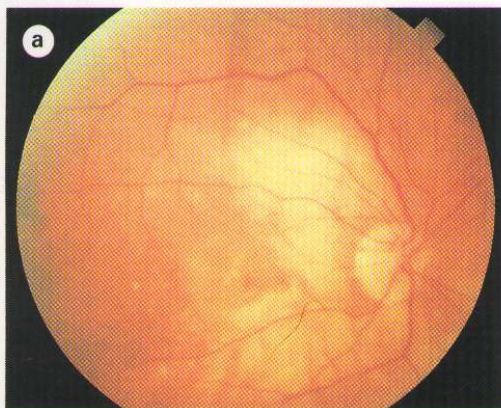
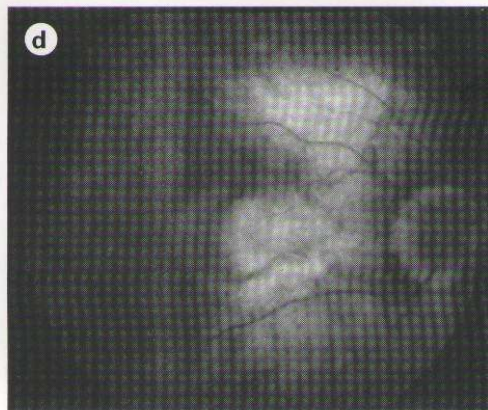
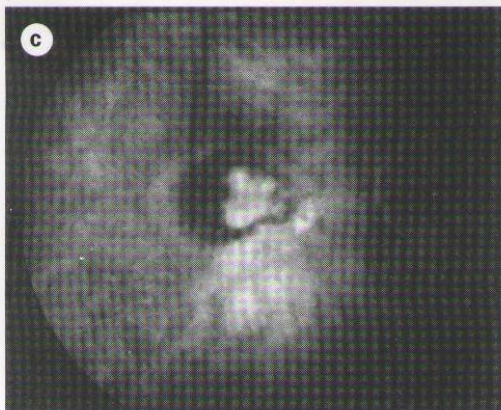


Fig. 13.65
(a) Exudative AMD; (b–d) FA shows classic juxtafoveal CNV



b. Poor visual acuity (6/36 or less) is often a contraindication because the CNV is likely to be subfoveal. In fact only about 10% of eyes are suitable for treatment at first presentation.

3. Technique

- Visual acuity is measured for near and distance.
- The area of the scotoma or visual distortion is documented on the Amsler grid.
- A good-quality FA, not more than 72 hours old, should be available (see Fig. 13.65).

d. Selected frames of the FA are projected onto a screen so that the CNV can be precisely localized in relation to visible retinal landmarks.

e. The perimeter of the lesion is treated with overlapping 200 μ m (0.2–0.5 second) burns and then the entire area is covered with high-energy burns. Treatment must extend beyond the margins of the membrane and produce a confluent, intense white burn.

f. A post-treatment fundus photograph is taken to document the extent of treatment.

4. Follow-up should be meticulous so that persistent or recurrent CNV is detected early.

- a. Initial follow-up is after 1–2 weeks with an FA to ensure adequacy of treatment (Fig. 13.66).
- b. Re-treatment is indicated if there is true persistence or recurrence of CNV more than 200 μm from the centre of the fovea.
- c. Because recurrences can occur several years after initially successful treatment, it is important for the patient to continue to self-monitor progress with the regular use of the Amsler grid. On detection of any fresh distortion or scotoma, immediate examination should be arranged.

5. Results are frequently disappointing for the following reasons:

- Using FA as a guide, only a very small proportion of eyes are eligible for treatment.
- Even after treatment in eligible eyes, the recurrence rate is greater than 50%—most recurrent lesions are subfoveal.

Photodynamic therapy

1. Principles. Verteporfin, a photosensitizer or light-activated compound, is injected intravenously. It is then activated focally by illumination with light from a diode laser source at a wavelength (689 nm) that corresponds to an absorption peak of the compound. The main advantage of photodynamic therapy is the ability to selectively damage tissue, attributable to both preferential localization of the photosensitizer to the CNV and irradiation confined to the target tissue. The CNV is irradiated with light levels far lower than those required for thermal destruction by argon laser therapy, enabling treatment of subfoveal CNV.

2. Indications

- a. **Definite** indications are subfoveal/juxtafoveal, predominantly classic CNV, not larger than 5400 μm in eyes with a visual acuity of 6/60 or better.
- b. **Possible** indications are lesions greater than 5400 μm , juxtapapillary CNV with subfoveal extension and CNV from other causes.

3. Contraindications are <50% classic CNV and pure occult CNV but these may change in future studies.

4. Technique

- Verteporfin (6 mg/kg body weight) is infused intravenously over 10 minutes.
- Five minutes later diode laser is applied to the CNV for 83 seconds.
- Re-treatment is applied to areas of persistent or new leakage at 3-monthly intervals until the entire CNV is obliterated.

5. Results in predominantly classic CNV are encouraging with stability or improvement of visual acuity in 60% of cases at 24 months.

Experimental therapies

1. Surgery

- a. **Submacular surgery** involves the surgical removal of submacular blood, CNV or both. Exact indications and benefits for this type of surgery are currently unknown. Preliminary results suggest a high recurrence rate and the procedure carries a significant risk of complications resulting in visual loss and necessitating further surgical intervention.

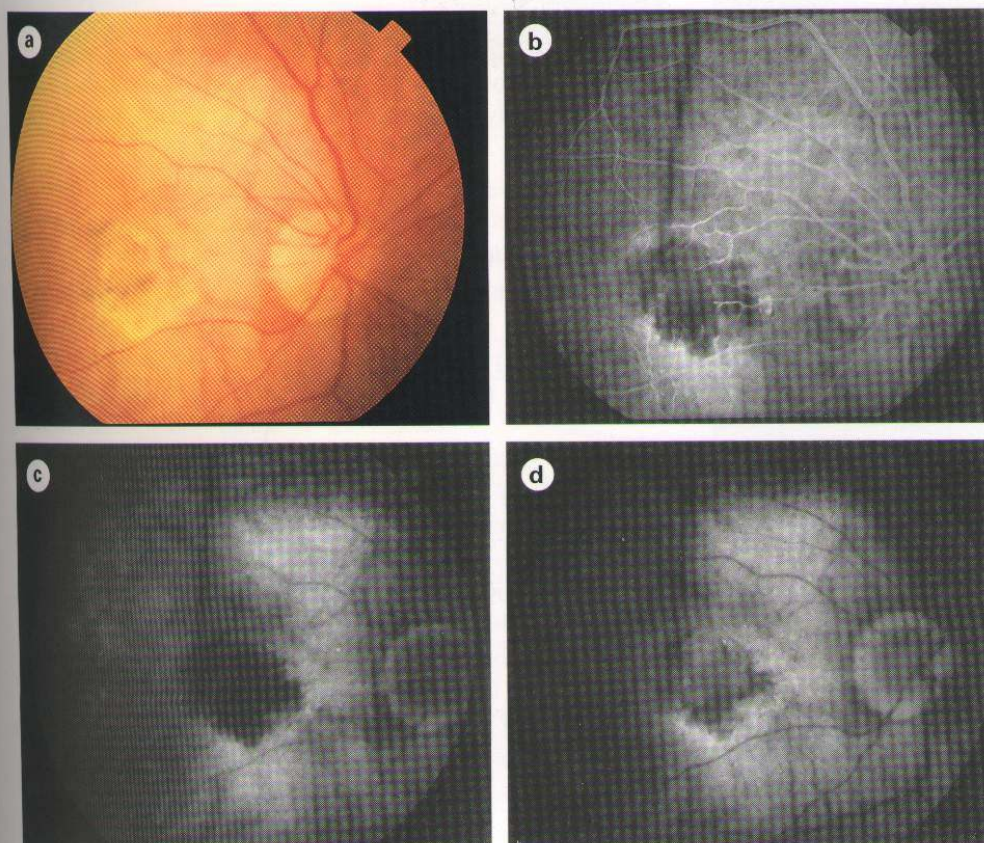


Fig. 13.66

(a) Same eye 2 weeks following laser photocoagulation; (b–d) FA showing successful treatment (mild staining around the margin of the treated area is normal)

b. Macular translocation is aimed at surgically moving the fovea away from the CNV. The procedure involves chorioscleral folding, vitrectomy and subretinal infusion of balanced salt solution to induce a temporal retinal detachment. Fluid–air exchange is then performed followed by postoperative upright positioning. If appropriate, the CNV may be photocoagulated without the risk of foveal damage. Success is dependent on effective transposition of the fovea away from the diseased CNV complex and the degree of preoperative foveal function. Indications for this modality are still evolving.

c. Pneumatic displacement of submacular haemorrhage involves injection of gas into the vitreous cavity in order to displace the blood from the fovea. This procedure may also be performed with a fibrinolytic agent called tissue plasminogen activator (tPA).

2. Transpupillary thermotherapy with a diode laser (810 nm) may be used for predominantly occult CNV. It has been speculated that this will affect the deeper choroidal vasculature, while sparing the sensory retina. At present there is no data to support this hypothesis.

Age-related macular hole

Age-related (idiopathic) macular holes typically affect elderly females and are caused by progressive tangential vitreo-retinal traction at the fovea. Presentation is with severe impairment of central vision, which is often noticed when the fellow eye is closed. In other cases a macular hole first becomes apparent when vision in the fellow eye becomes impaired due to hole formation or other pathology. The diagnosis may also sometimes be made by chance. The risk of involvement of the fellow eye at 5 years is about 15%.

Staging (Fig. 13.67)

1. Stage 1a (impending) macular hole is rarely seen clinically and is usually detected in a patient with a full-thickness macular hole (FTMH) in the other eye. It is

characterized by a yellow spot at the foveola (Fig. 13.68), which represents an intrafoveal cyst which can be confirmed on ocular coherence tomography (see Fig. 13.72).

2. Stage 1b (occult) macular hole results from centrifugal displacement of the foveolar retina and xanthophyll. It is characterized by a yellow ring with a bridging interface of vitreous cortex. These findings may be associated with recent mild decrease in visual acuity or metamorphopsia. About 50% of stage 1 holes resolve following spontaneous vitreofoveolar separation.

3. Stage 2 (early FTMH) is characterized by an eccentric, oval, crescentic or horseshoe-shaped retinal defect less than 400 μm in diameter with or without an overlying prefoveal opacity (pseudo-operculum) (see Fig. 13.73). True opercula are rare and the pseudo-operculum is formed by the contracted prefoveal cortical vitreous. Progression from stage 1 to stage 2 takes between 1 week and several months.

4. Stage 3 (established FTMH) is characterized by a round retinal defect greater than 400 μm in diameter with an attached posterior vitreous face with or without an overlying pseudo-operculum (see Fig. 13.74).

5. Stage 4 is characterized by enlargement of the round defect which is now surrounded by a cuff of subretinal fluid (see Fig. 13.75) and exhibits tiny yellowish deposits at the base of the crater (Fig. 13.69). The posterior vitreous is completely detached, often evidenced by a Weiss ring (see Fig. 12.20). Visual acuity is decreased primarily due to the absence of photoreceptors within the central defect with a resultant absolute central scotoma. In addition, the surrounding cuff of subretinal fluid and secondary retinal elevation cause a relative scotoma surrounding the absolute central scotoma. Visual acuity tends to deteriorate progressively, stabilizing at 6/60 or worse as the hole reaches its maximal diameter. Some patients may achieve better acuity by employing eccentric fixation.

NB: An FTMH may rarely spontaneously resolve and visual acuity improve.

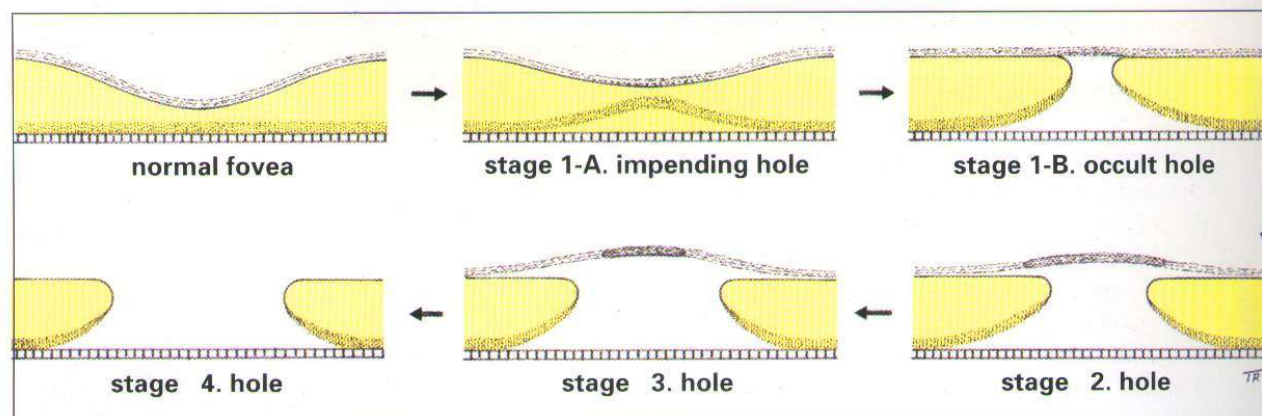


Fig. 13.67
Stages of age-related macular hole (see text)

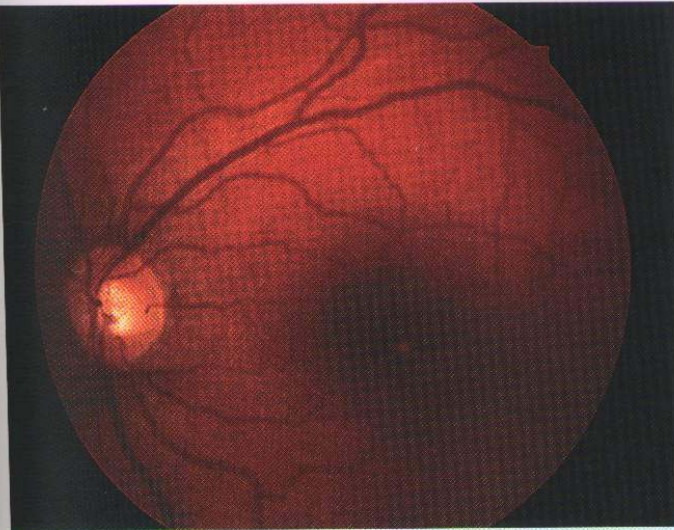


Fig. 13.68
Stage 1a macular hole

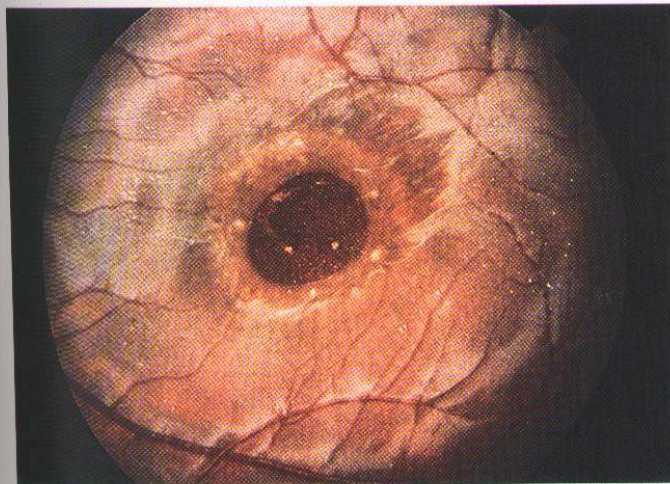


Fig. 13.69
Full-thickness macular hole


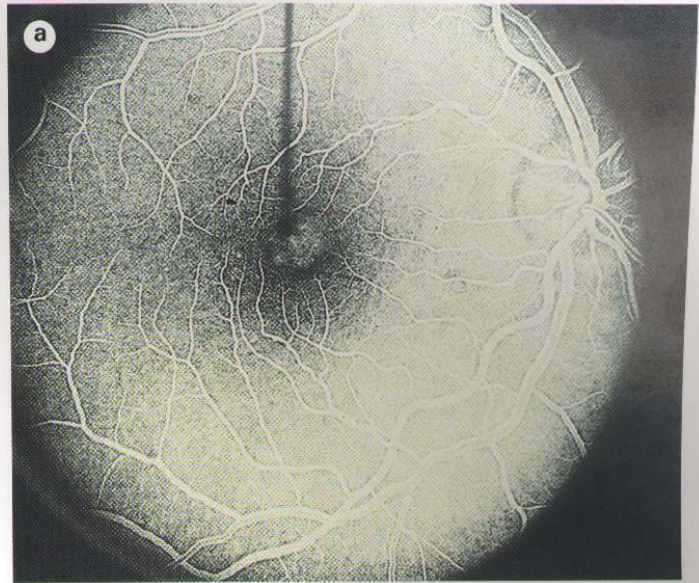


Fig. 13.70
FA of full-thickness macular hole (see text) (Courtesy of Wilmer Institute)

Diagnostic tests

1. **Watzke–Allen** test is performed by projecting a narrow slit beam over the centre of the hole both vertically and horizontally with a 90 D or 78 D lens. A patient with a macular hole will report that the beam is broken or thinned.
2. **Laser aiming beam test** is performed by projecting a 50 μ m spot of a laser aiming beam (e.g. He-Ne) at the centre of the hole. A patient with a macular hole will report that the spot has disappeared.
3. **FA** shows a corresponding area of hyperfluorescence (Fig. 13.70a) resulting from unmasking of background choroidal fluorescence caused by a window defect in xanthophyll due to centrifugal displacement (Fig. 13.70b).
4. **Optical coherence tomography (OCT)** provides high resolution optical sections of the retina and affords measurement of retinal thickness. It is useful in the diagnosis and staging of macular holes. It can even measure the volume of a full-thickness macular hole.

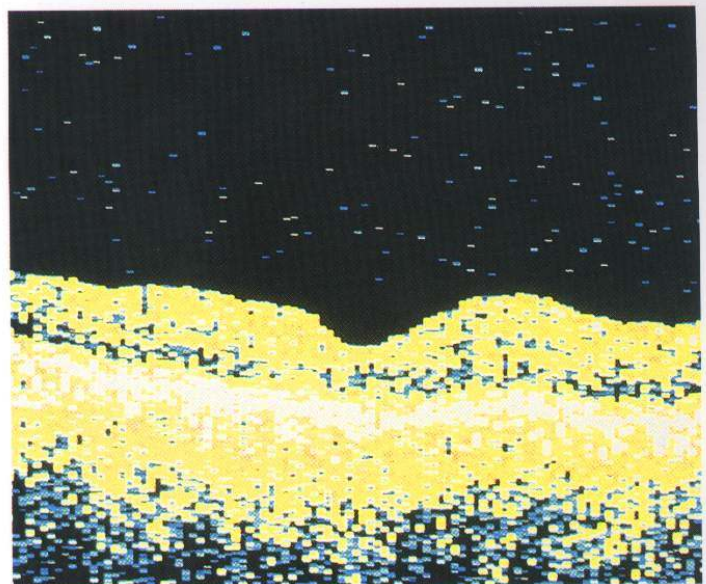


Fig. 13.71
OCT of normal fovea (Courtesy of R. Spaide)

Figure 13.71 shows a normal fovea, Figure 13.72 a stage 1a hole (intrafoveal cyst), Figure 13.73 shows a stage 2 hole with an overlying pseudo-operculum, Figure 13.74 shows a full-thickness stage 3 hole and Figure 13.75 shows a stage 4 hole with a cuff of surrounding subretinal fluid.

Surgical treatment

1. Indications are FTMH up to stage 3, associated with a visual acuity worse than 6/18 and a duration less than 1 year.

2. Technique

a. Conventional vitrectomy consists of removal of the cortical vitreous, internal limiting membrane and gas–fluid exchange followed by strict postoperative face-down positioning. It has been postulated that hole closure is the result of centripetal movement of previously displaced paracentral photoreceptors and not simply re-approximation of the retinal edges to the RPE.

b. 'Chemical vitrectomy' is a new and less complicated method of treating stage 3 macular holes. An enzyme (plasmin) is injected into the vitreous to chemically

detach the vitreous from the retina, without manipulation of the posterior hyaloid. The vitreous is also lavaged with an infusion pipe and vitreous cutter and then 70–80% of the vitreous cavity is filled with 16% C_3F_8 . Postoperatively the patient is positioned face-down.

3. Results. Following successful surgery, visual improvement is achieved in 80% of eyes, with a final visual acuity of 6/12 or better in up to 65%. Figure 13.76a shows an FTMH and Figure 13.76b the postoperative appearance following successful surgery.

4. Complications are those associated with vitrectomy, such as retinal detachment and acceleration of cataract. Permanent visual field defects, often inferotemporal, may develop.

Differential diagnosis

1. Other macular holes

a. High myopia, if associated with posterior staphyloma, may be associated with macular hole formation which can lead to retinal detachment. The subretinal fluid is confined to the posterior pole and seldom spreads to the equator.




Fig. 13.72
OCT of stage 1a macular hole (Courtesy of R. Spaide)

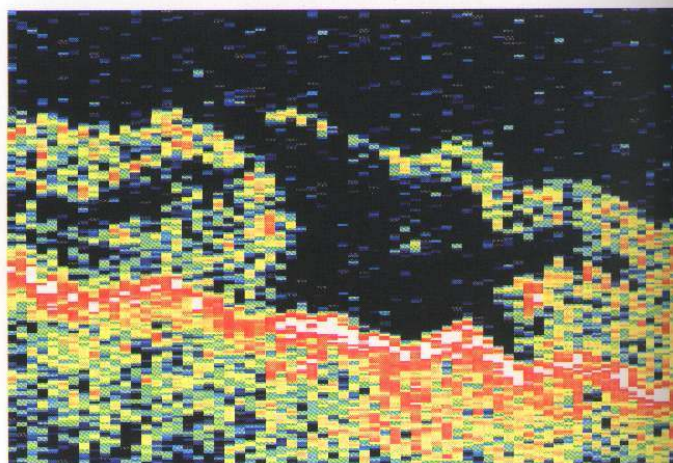


Fig. 13.74
OCT of stage 3 macular hole (Courtesy of V. Tanner)

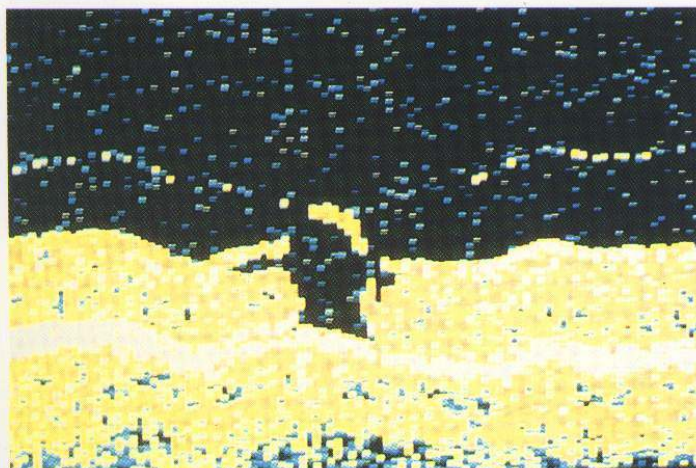


Fig. 13.73
OCT of stage 2 macular hole (Courtesy of R. Spaide)

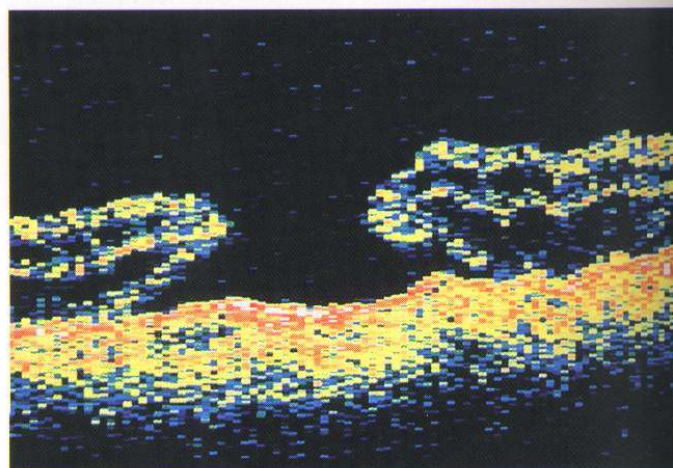


Fig. 13.75
OCT of stage 4 macular hole (Courtesy of V. Tanner)

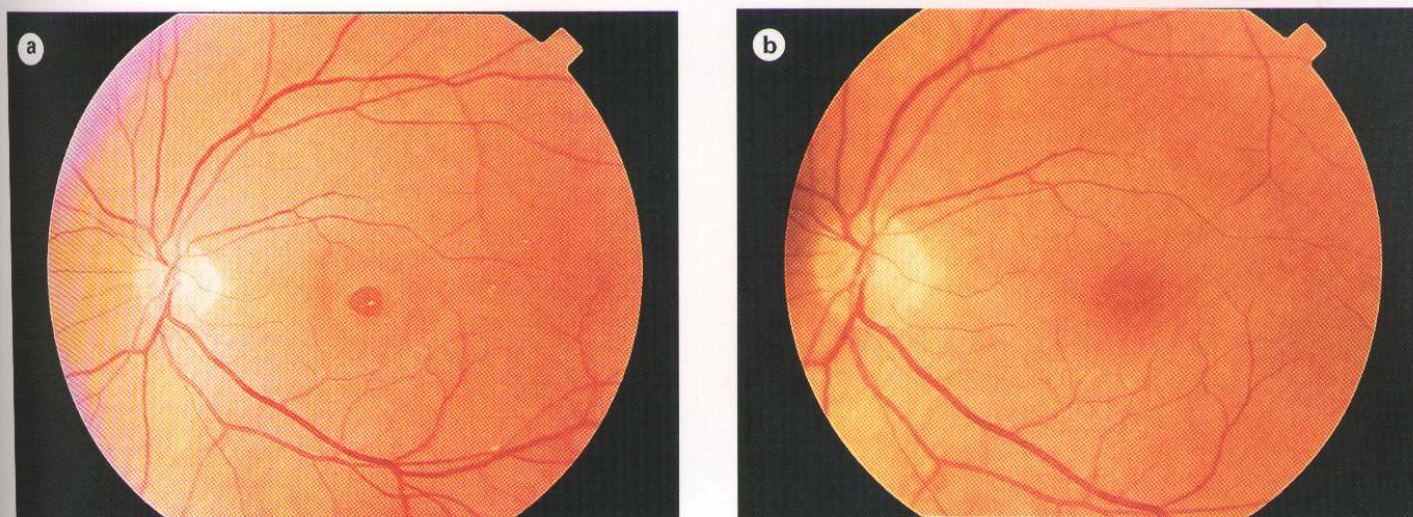


Fig. 13.76
(a) Full-thickness macular hole; (b) following successful closure (Courtesy of S. Milewski)

b. **Blunt ocular trauma** may cause a macular hole as a result of either vitreous traction or commotio retinae in which there is disruption of photoreceptors and subsequent hole formation.

2. Macular pseudo-holes

- Within premacular fibrosis* (Fig. 13.77).
- Lamellar hole* resulting from long-standing severe cystoid macular oedema.
- White dot fovea* is an uncommon asymptomatic condition. White dots may be arranged diffusely or in the form of a ring along the margin of the foveola. The latter pattern simulates the appearance of a true macular hole with a cuff of fluid.

Central serous retinopathy

Central serous retinopathy (CSR, central serous chorio-retinopathy) is a typically sporadic, self-limited disease of

young or middle-aged adult males with type A personality. It is characterized by a usually unilateral, localized detachment of the sensory retina at the macula with or without associated PED. It is uncertain whether the primary pathology involves hyperpermeability of the RPE or the choroidal vasculature. Factors reported to induce or aggravate CSR include emotional stress, hypertension, systemic lupus erythematosus and the administration of systemic steroids.

Clinical features

- Presentation** is with unilateral blurred vision associated with a positive relative scotoma and micropsia and/or metamorphopsia. Occasionally the condition is extrafoveal and asymptomatic.
- Visual acuity** is usually reduced to 6/9–6/12 and often correctable to 6/6 with a weak 'plus' lens. The elevation of the sensory retina gives rise to an acquired hypermetropia with disparity between the subjective and objective refraction of the eye.

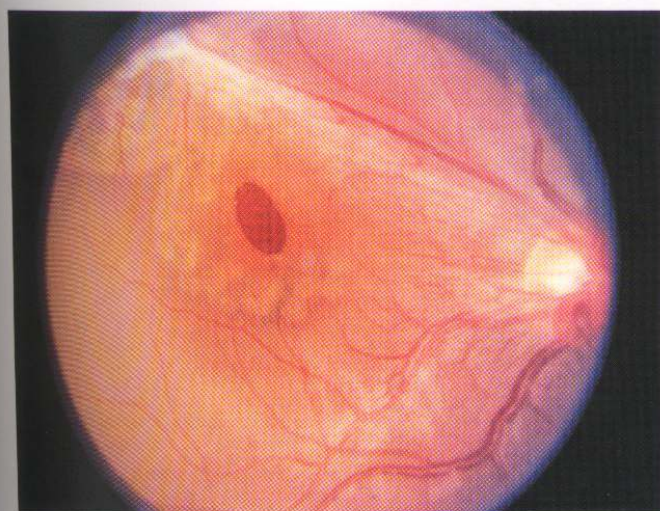


Fig. 13.77
Macular pseudo-hole within premacular fibrosis

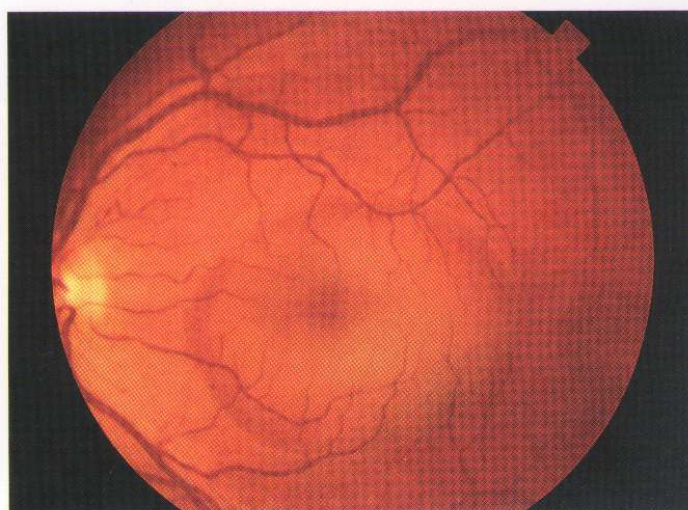


Fig. 13.78
Central serous retinopathy

3. Fundus

- A round or oval detachment of the sensory retina is present at the posterior pole (Fig. 13.78).
- The subretinal fluid may be clear or turbid and small precipitates may be present on the posterior surface of the sensory detachment.
- Occasionally, an abnormal focus in the RPE, through which fluid has leaked from the choriocapillaris into the subretinal space, can be detected.
- In some cases a small PED may be evident within the serous detachment.

4. FA shows one of the following pictures:

a. *Smoke-stack* appearance which evolves as follows:

- The early phase shows a small hyperfluorescent spot due to leakage of dye through the RPE (Fig. 13.79b). More than one leak may be present.
- During the late venous phase, fluorescein passes into the subretinal space and ascends vertically (like a smoke-stack) (Fig. 13.79c) from the point of leakage until the upper border of the detachment.
- The dye then spreads laterally, taking on a 'mushroom' or 'umbrella' configuration (Fig. 13.79d), until the entire area of detachment is filled.

b. *Ink-blot* appearance is less common and evolves as follows:

- The early phase shows a small hyperfluorescent spot (Fig. 13.80b).
- The spot gradually enlarges centrifugally (Fig. 13.80c and d) until the entire detachment is filled with dye.

Course

1. **Short** course. Most commonly, spontaneous absorption of subretinal fluid occurs within 1–6 months with return to normal, or near normal, visual acuity.
2. **Prolonged** course. In some patients CSR lasts longer than 6 months but spontaneously resolves within 12 months. Even if visual acuity returns to normal, some degree of subjective visual impairment such as micropsia may persist, but seldom causes any significant disability.
3. **Chronic** course. In a minority of cases, the condition lasts longer than 12 months and is characterized by progressive RPE changes associated with a permanent impairment of visual acuity and the occasional development of CNV. FA shows granular hyperfluorescence with one or more leaks. This may be a consequence of either multiple recurrent attacks or prolonged detachment, although a minority of patients do not have a past history of typical CSR, and in some the changes are bilateral.

Treatment

Argon laser photocoagulation to the RPE leak or detachment achieves speedier resolution and lowers the recurrence rate but does not influence the final visual outcome. It is advisable to wait for 4 months before considering treatment of the first attack and 1 month for recurrences. Treatment is contraindicated if the leak is near or within the FAZ.

1. **Technique.** Two or three low- to moderate-intensity burns are applied to the leakage site (200 μ m, 0.2 seconds) to produce mild greying of the RPE.

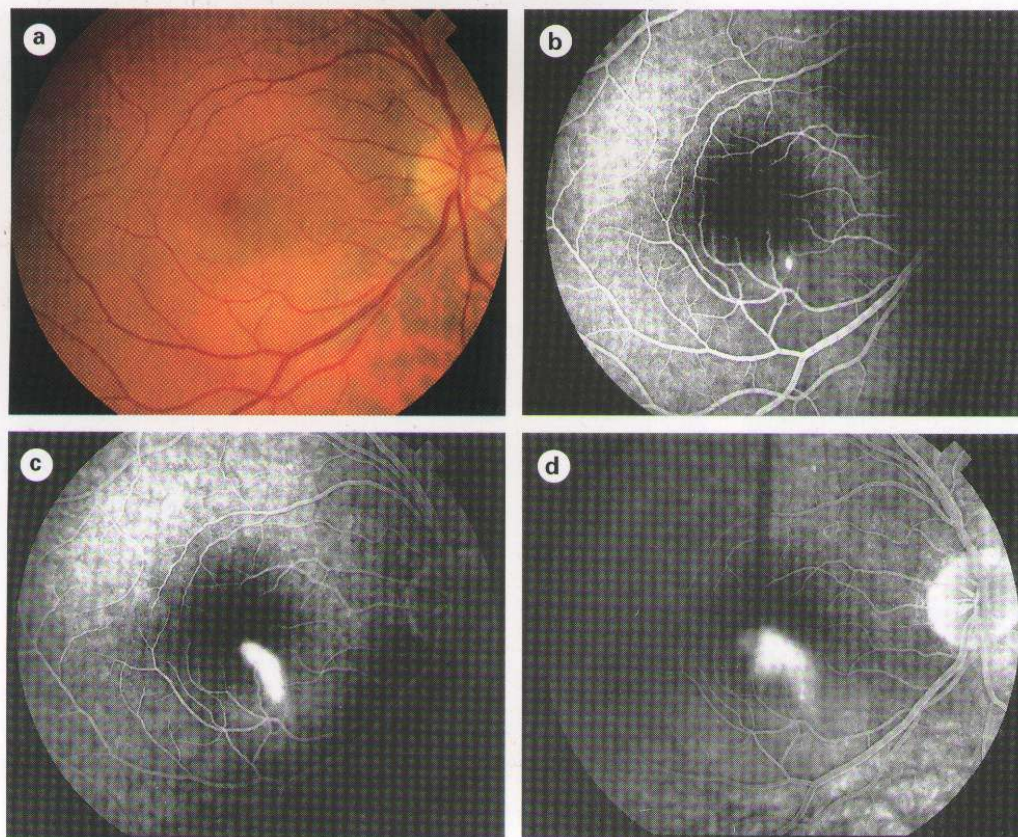
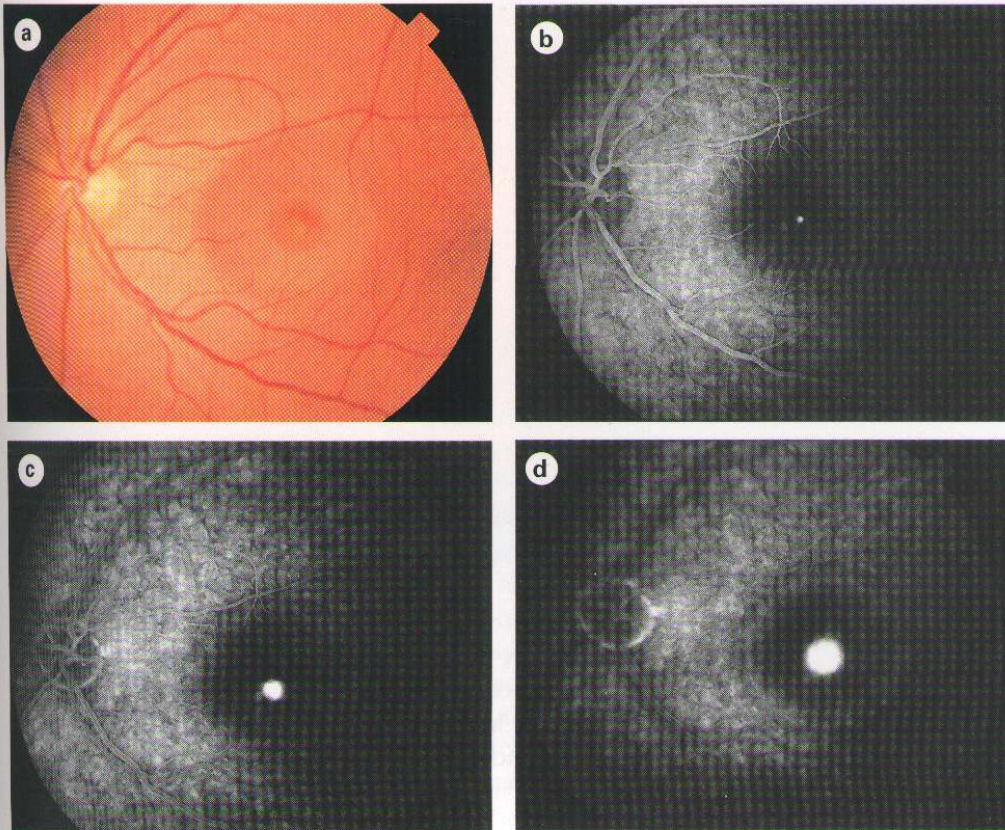


Fig. 13.79
(a) Central serous retinopathy;
(b–d) FA showing a smoke-stack
appearance (see text) (Courtesy of S.
Milewski)

**Fig. 13.80**

(a) Central serous retinopathy;
(b-d) FA showing an ink-blot
appearance (Courtesy of S. Milewski)

2. **Careful follow-up** is required as 2–5% of treated eyes subsequently develop CNV.

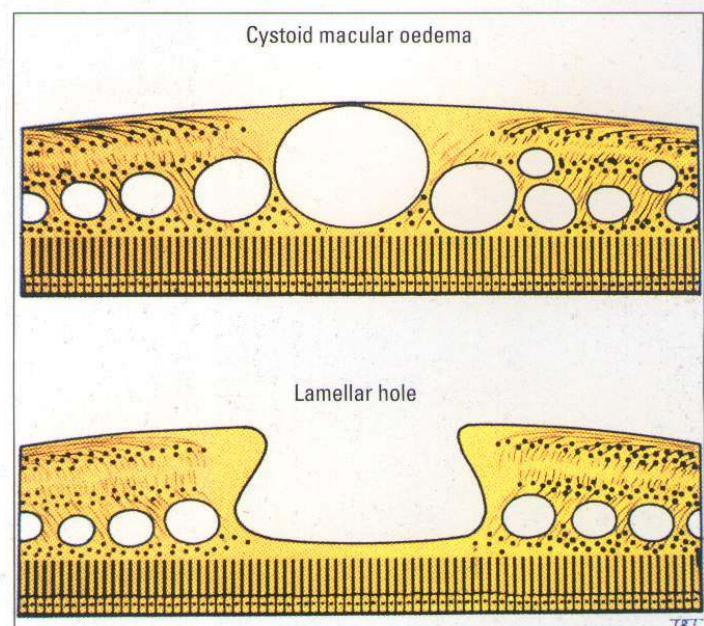
Differential diagnosis of sensory macular detachment

1. **Congenital optic disc anomalies**, most frequently optic disc pit (see Fig. 13.111) and occasionally tilted disc, may be associated with serous macular detachment. Unless the optic disc is examined carefully the diagnosis may be missed.
2. **Choroidal tumours** with a predilection for the posterior pole such as circumscribed choroidal haemangioma and metastatic carcinoma.
3. **Unilateral acute idiopathic maculopathy** is a rare self-limiting condition that typically causes sudden unilateral visual loss in a young person.
4. **Choroidal neovascularization**, particularly if idiopathic.
5. **Harada disease** during the stage of multifocal detachments of the sensory retina may mimic multifocal CSR.

Cystoid macular oedema

Cystoid macular oedema (CMO) is the result of accumulation of fluid in the outer plexiform and inner nuclear layers of the

retina centred about the foveola and the formation of fluid-filled cyst-like changes. In the short term, CMO is usually innocuous; long-standing cases, however, usually lead to coalescence of the fluid-filled microcysts into large cystoid spaces and subsequent lamellar hole formation at the fovea with irreversible damage to central vision (Fig. 13.81). CMO is a common and non-specific condition that may occur with any type of macular oedema.

**Fig. 13.81**

Cystoid macular oedema resulting in lamellar hole formation

Clinical features

1. Presentation varies with the cause. Visual acuity may already be impaired by pre-existing disease such as branch vein occlusion. In other cases without pre-existing disease such as after cataract surgery, the patient complains of impairment of central vision associated with a positive central scotoma.

2. Signs

- Slit-lamp biomicroscopy shows loss of the foveal depression, thickening of the retina and multiple cystoid areas in the sensory retina (Fig. 13.82).
- In early cases cystoid changes may be difficult to discern and the main finding is a yellow spot at the foveola.

3. FA

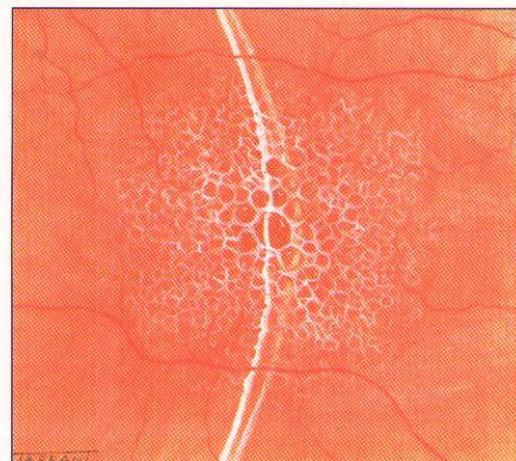
- The arteriovenous phase shows mild parafoveal hyperfluorescence due to early leakage (Fig. 13.83b).
- The late venous phase shows increasing hyperfluorescence and coalescence of the focal leaks (Fig. 13.83c).
- The late phase shows a 'flower-petal' pattern of hyperfluorescence (Fig. 13.83d) caused by accumulation of dye within microcystic spaces in the outer plexiform layer of the retina, with its radial arrangement of fibres about the centre of the foveola (Henle layer).

Causes and treatment

1. Retinal vascular disease (see Chapter 14).

- a. Causes* include diabetic retinopathy, retinal vein occlusion, idiopathic retinal telangiectasia, retinal artery macroaneurysm and radiation retinopathy.

Fig. 13.82
Appearance of cystoid macular oedema on slit-lamp biomicroscopy



b. Treatment by laser photocoagulation may be appropriate in selected cases.

2. Intraocular inflammatory disease (see Chapter 10).

- a. Causes* include intermediate uveitis, birdshot retinochoroidopathy, multifocal choroiditis with panuveitis, toxoplasmosis, cytomegaloviral retinitis, Behçet disease and scleritis.
- b. Treatment* is aimed at controlling the inflammatory process with steroids or immunosuppressive agents. Systemic carbonic anhydrase inhibitors may be beneficial in CMO associated with intermediate uveitis.

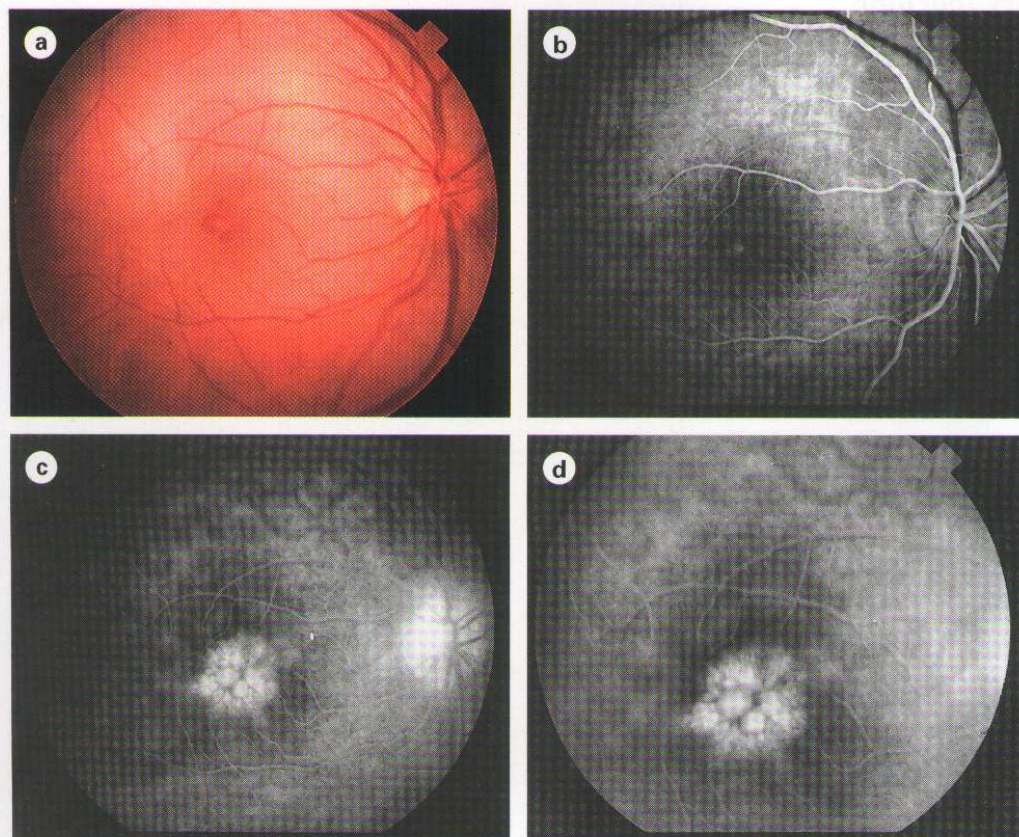


Fig. 13.83
(a) Cystoid macular oedema; (b–d) FA showing leakage (see text)
(Courtesy of S. Milewski)

3. **Post-cataract surgery.** CMO is rare following uncomplicated surgery and usually resolves spontaneously.

a. **Risk factors** for visually significant CMO include anterior chamber IOL implantation, secondary lens implantation, operative complications such as posterior capsular rupture, vitreous loss and vitreous incarceration into the incision site, diabetes and a history of CMO in the other eye. Peak incidence is at 6–10 weeks after surgery, although the interval may be much longer.

b. **Treatment** involves correction of the underlying cause, if possible. For example, vitreous incarceration in the anterior segment may be amenable to anterior vitrectomy or YAG laser disruption of vitreous adhesions. As a last resort it may be necessary to remove an anterior chamber IOL. If a correctable cause is not present, treatment is difficult although many cases resolve spontaneously within 6 months. Treatment of persistent CMO involves the following measures:

- Systemic carbonic anhydrase inhibitors.
- Steroids, given topically or by posterior periocular injection, combined with topical non-steroidal anti-inflammatory drugs (NSAIDs) such as ketorolac 0.5% (Acular) administered q.i.d. may be beneficial even in long-standing and clinically significant CMO. Unfortunately, in many cases CMO recurs when treatment is discontinued, so that long-term medication may be required.
- Pars plana vitrectomy may be useful for CMO refractory to medical therapy even in eyes without apparent vitreous disturbance.

4. **After other surgical procedures**

a. **Causes** include YAG laser capsulotomy, peripheral retinal cryotherapy and laser photocoagulation. The risk of CMO is reduced if capsulotomy is delayed for 6 months or more after cataract surgery. Rarely, CMO may develop following scleral buckling, penetrating keratoplasty and glaucoma filtration surgery.

b. **Treatment** is unsatisfactory although the CMO is often mild and self-limited.

5. **Drug-induced**

a. **Causes** include topical adrenaline 2% especially in the aphakic eye, topical latanoprost and systemic nicotinic acid.

b. **Treatment** involves cessation of medication.

6. **Retinal dystrophies** (see Chapter 15).

a. **Causes** include retinitis pigmentosa, gyrate atrophy and dominantly inherited CMO.

b. **Treatment** with systemic carbonic anhydrase inhibitors may be beneficial in CMO associated with retinitis pigmentosa.

7. **Vitreomacular traction syndrome** is characterized by partial peripheral vitreous separation with persistent posterior attachment to the macula. This results in anteroposterior and tangential traction vectors. Chronic CMO due to anteroposterior traction is common and may respond to vitrectomy.

8. **Macular epiretinal membranes** may occasionally cause CMO by disrupting the perifoveal capillaries. Surgical excision of the membrane may be beneficial in selected cases.

Myopic maculopathy

High myopia is associated with progressive, excessive elongation of the globe often followed by degenerative changes involving the sclera, choroid, Bruch membrane, RPE and sensory retina. Fundus changes usually occur when the myopia measures 6 D or more and the axial length 25 mm or more.

General changes

- The optic disc is often tilted and may be surrounded by chorioretinal atrophy (Fig. 13.84)
- A pale tessellated appearance due to attenuation of the RPE.
- Severe chorioretinal atrophy involving the posterior pole characterized by visibility of the larger choroidal vessels and eventually the sclera.
- Peripheral chorioretinal atrophy (pavingstone degeneration) (see Fig. 12.73).

Macular changes

1. **Geographic atrophy** of the RPE and choriocapillaris (Fig. 13.85).

2. **'Lacquer cracks'** develop in about 5% of highly myopic eyes. They represent large breaks in Bruch membrane and are characterized by fine, irregular, yellow lines, often branching and criss-crossing (Fig. 13.86).

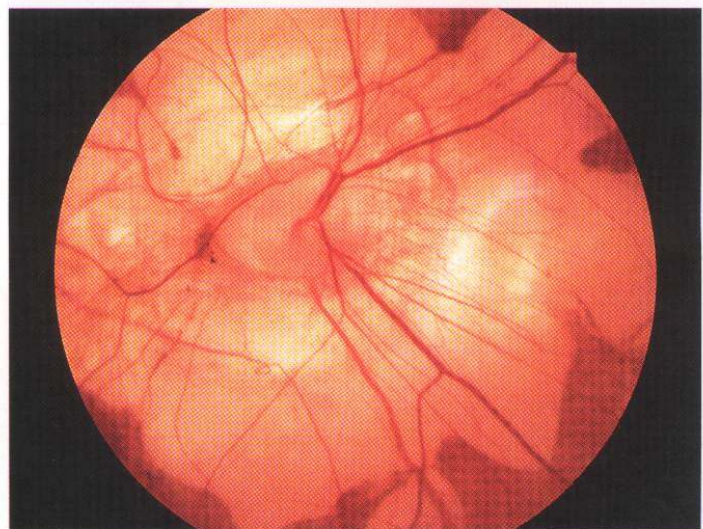


Fig. 13.84

Tilted optic disc with myopic chorioretinal atrophy

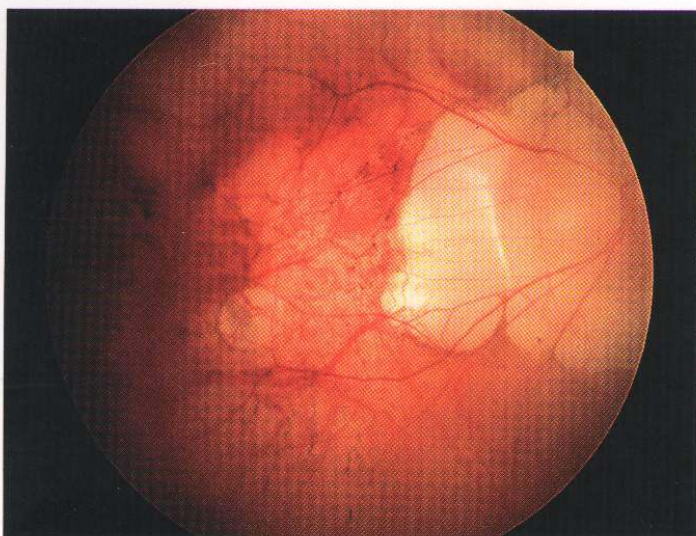


Fig. 13.85
Geographic atrophy of the RPE and choriocapillaris at the macula and severe parapapillary chorioretinal atrophy in high myopia

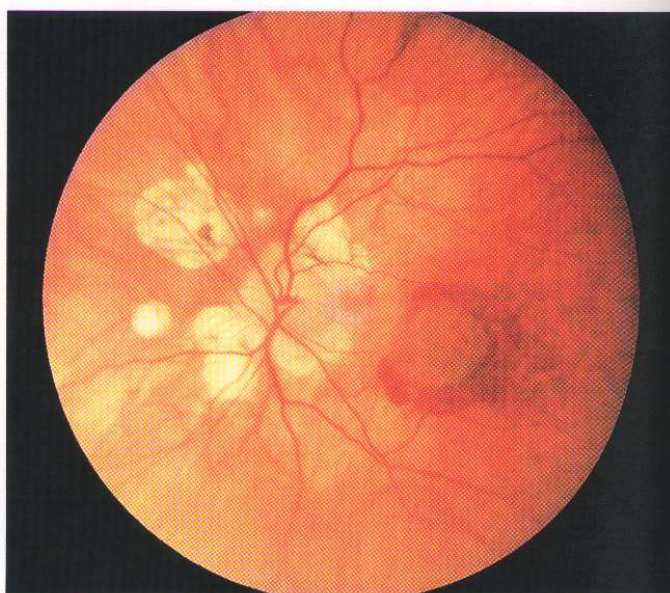


Fig. 13.87
Subretinal haemorrhage from CNV in high myopia

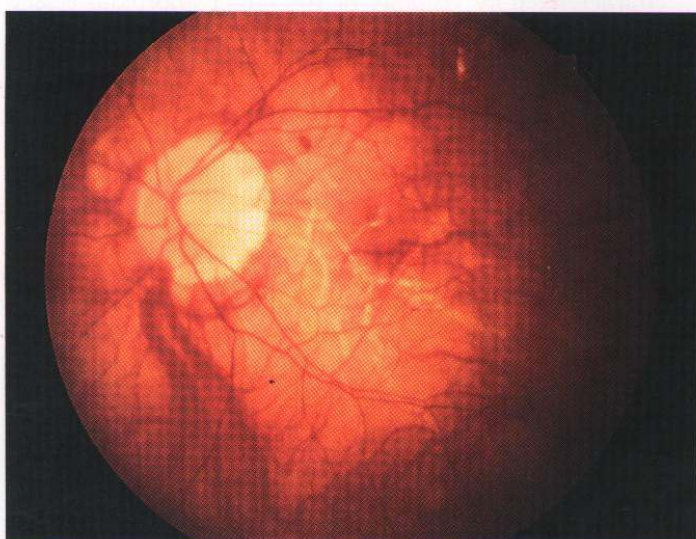


Fig. 13.86
Lacquer cracks in high myopia

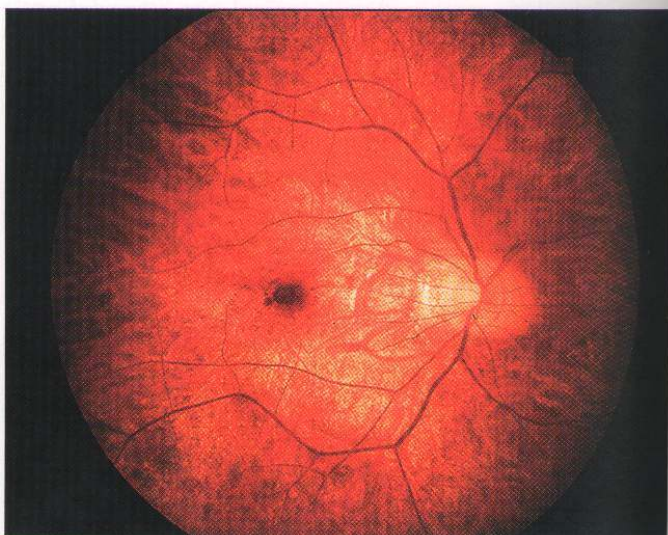


Fig. 13.88
Small, fovea 'coin' haemorrhage not associated with CNV in high myopia

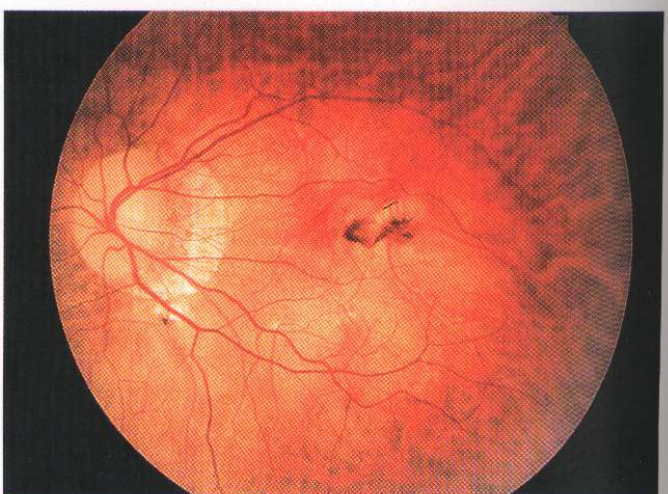


Fig. 13.89
Foerster-Fuchs spot in high myopia

3. **Exudative** maculopathy secondary to CNV associated with 'lacquer cracks' (Fig. 13.87). The prognosis for central vision is, however, better than in exudative AMD because CNV in highly myopic eyes tends to be relatively self-limited and not associated with subretinal fibrovascular scarring.
4. **Subretinal 'coin' haemorrhages** may develop from lacquer cracks in the absence of CNV and are usually transient (Fig. 13.88).
5. **Foerster-Fuchs spot** is a raised, circular, pigmented lesion that may develop after a macular haemorrhage has absorbed (Fig. 13.89).
6. **Macular hole**, which unlike an age-related macular hole, may result in retinal detachment.

Associations of high myopia

1. Ocular

- Retinal detachment due to a combination of vitreous degeneration, lattice degeneration and retinal breaks (macular holes, atrophic peripheral holes and tears) (see Chapter 12).
- Cataract (posterior subcapsular or early-onset nuclear sclerosis).
- Increased prevalence of primary open-angle glaucoma, pigmentary glaucoma and steroid responsiveness.
- Retinopathy of prematurity may be associated with the subsequent development of myopia.

2. **Systemic** associations include Stickler, Marfan, Ehlers-Danlos and Pierre-Robin syndromes.

Macular epiretinal membrane

Macular epiretinal membranes (epiretinal gliosis) that develop at the vitreoretinal interface consist of proliferations of retinal glial cells which have gained access to the retinal surface through breaks in the internal limiting membrane. Such breaks may be created when the posterior vitreous detaches from the macula. The clinical appearance of an epiretinal membrane depends on its density and any associated distortion of the retinal vasculature. It is convenient to divide the condition into: (a) *cellophane maculopathy* and (b) *macular pucker*.

Causes

1. **Idiopathic** membranes affect otherwise healthy elderly individuals and are bilateral in about 10% of cases.
2. **Secondary**
 - a. **Retinal procedures** such as detachment surgery, photocoagulation and cryotherapy may either induce or worsen pre-existing macular epiretinal gliosis. Untreated, such membranes usually cause variable but permanent reduction of vision. Very occasionally,

however, a membrane may separate spontaneously from the retina.

b. **Other causes** include retinal vascular disease, intraocular inflammation and ocular trauma.

Cellophane maculopathy

This is caused by a thin translucent layer of epiretinal cells. It is common and usually idiopathic.

1. **Presentation** may be with mild metamorphopsia although frequently the condition is asymptomatic and discovered by chance.
2. **Visual acuity** may be normal or slightly reduced (6/9).
3. **Fundus**
 - Irregular light reflex or sheen at the macula (Fig. 13.90a).
 - The membrane itself is translucent and best detected with 'red-free' light. However, as it thickens and contracts it becomes more obvious and causes fine striae on the retinal surface and distortion of blood vessels which is highlighted on FA (Fig. 13.90b).
4. **Treatment** is not necessary.

Macular pucker

This is caused by thickening and contraction of the membrane. It is less common than cellophane maculopathy and may be idiopathic or secondary.

1. **Presentation** is with metamorphopsia and blurring of central vision.
2. **Visual acuity** is 6/12 or worse, depending on severity.
3. **Fundus**
 - Retinal wrinkling and white striae may obscure the underlying markedly tortuous retinal vasculature (Fig. 13.91a and b).
 - Associated findings include macular pseudo-holes within the membrane (see Fig. 13.77) and occasionally secondary chronic CMO.
4. **Pattern-reversal** visually evoked potential latencies are prolonged and amplitude is reduced.
5. **Treatment** by peeling of the membrane from the retinal surface often improves or eliminates distortion, and may improve visual acuity.

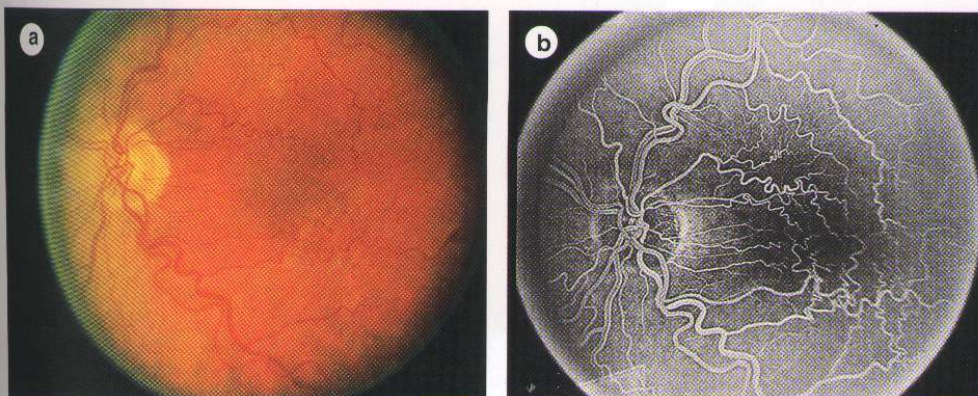


Fig. 13.90
Cellophane maculopathy (see text)
(Courtesy of Wilmer Institute)

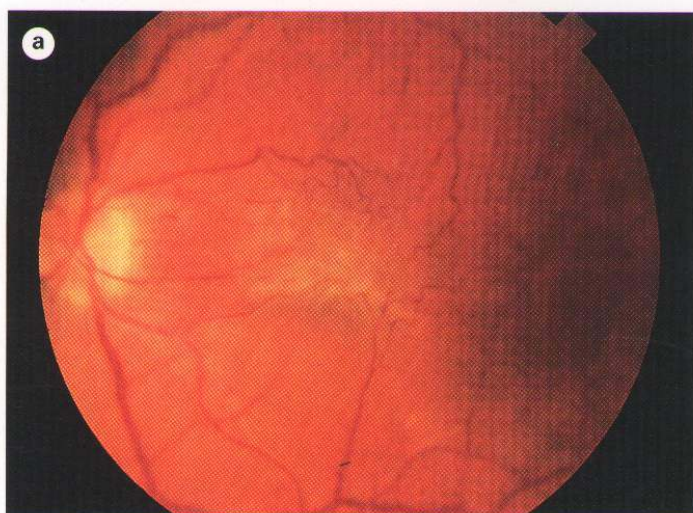
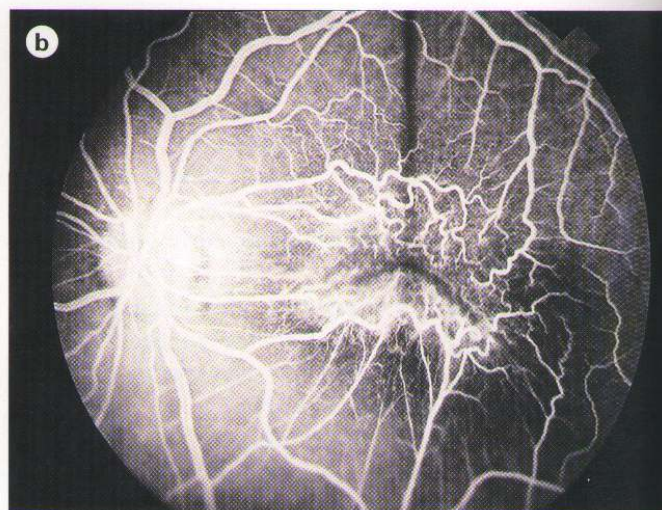


Fig. 13.91
Macular pucker (see text)



Angioid streaks

Angioid streaks represent crack-like dehiscences in the elastic layer of Bruch membrane due to an abnormal fragility of the lamina basalis caused by a degenerative process combined with calcium deposition. This results in secondary changes in the RPE and choriocapillaris.

Clinical features

1. Fundus

- Linear, reddish-brown lesions with irregular serrated edges lie beneath the normal retinal blood vessels. They

may initially be very subtle and easily overlooked (Fig. 13.92).

- Later they become more obvious due to secondary RPE atrophy or hyperplasia (Fig. 13.93).
- The streaks intercommunicate in a ring-like fashion around the optic disc and then radiate outwards from the parapapillary area.
- 'Peau d'orange' (orange skin) is pigmentary mottling at the posterior pole, most apparent temporal to the macula, and may antedate the appearance of angioid streaks.
- Salmon spots consisting of peripheral, focal chorioretinal scars may be present (Fig. 13.94).
- Optic nerve anomalies, occasionally present, include optic disc drusen (Fig. 13.95) and vascular loops.

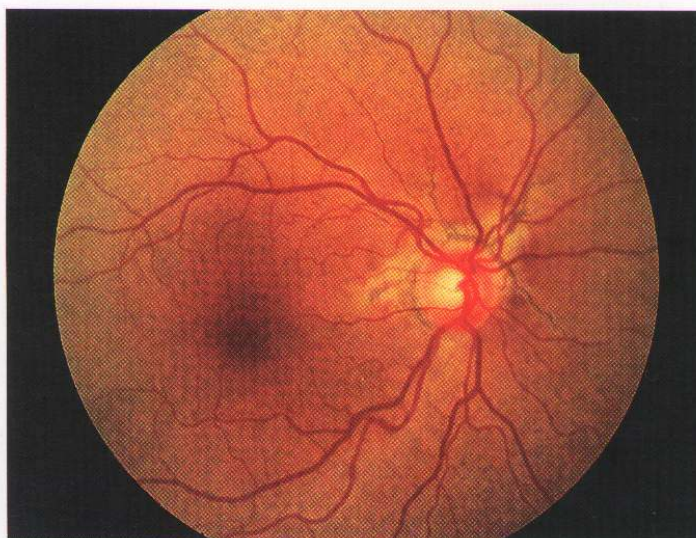


Fig. 13.92
Mild angioid streaks with extensive 'peau d'orange'

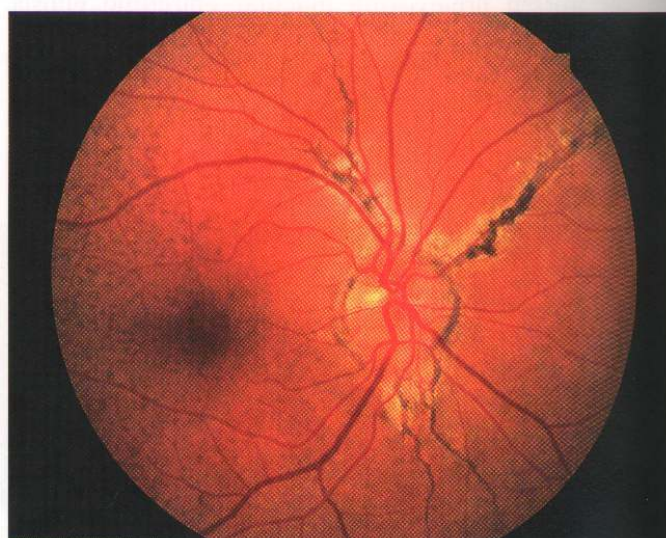


Fig. 13.93
Advanced angioid streaks

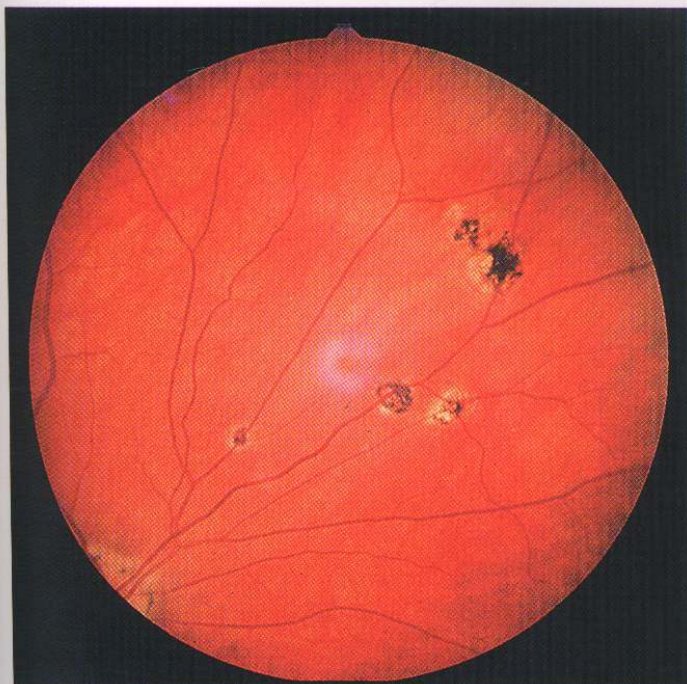


Fig. 13.94
Peripheral, focal, chorioretinal scars ('salmon spots') in an eye with angioid streaks

2. **FA** shows hyperfluorescence due to RPE window defects over the streaks (Fig. 13.96d) and is also useful in detecting CNV (Fig. 13.96c).

Prognosis

This is guarded because visual impairment occurs in over 70% of patients due to:

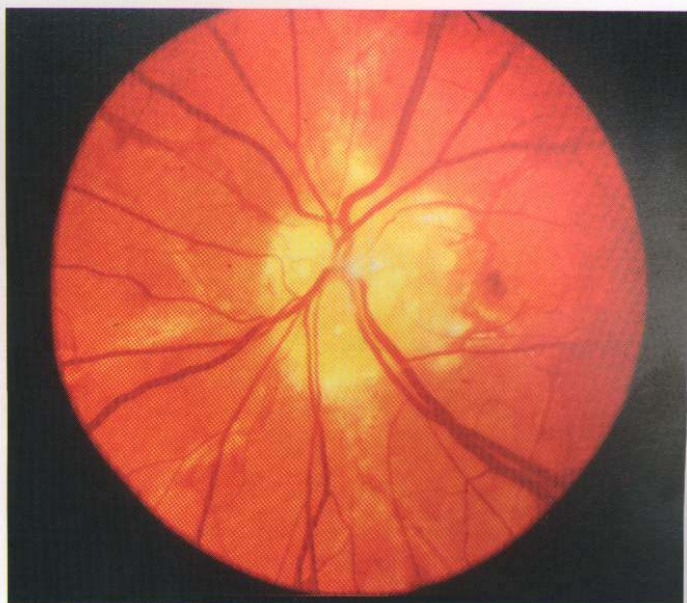


Fig. 13.95
Optic disc drusen in an eye with angioid streaks

1. **Exudative maculopathy** due to CNV (see Fig. 13.96a and c). Early treatment of CNV by laser photocoagulation may be appropriate in selected cases but carries a high risk of recurrence.
2. **Choroidal haemorrhage** may occur on trivial ocular trauma and result in a subfoveal haemorrhage (Fig. 13.97) and subsequent scarring (Fig. 13.98). Since these eyes are fragile patients should be advised not to participate in contact sports.
3. **Foveal involvement** by a streak.

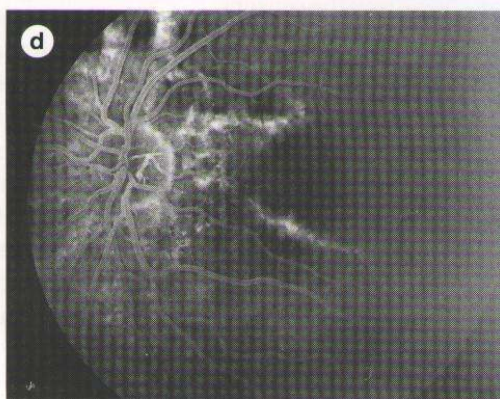
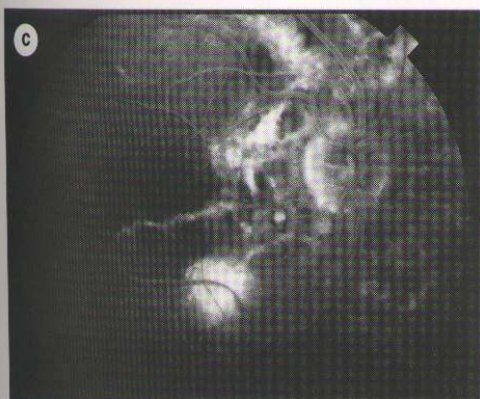
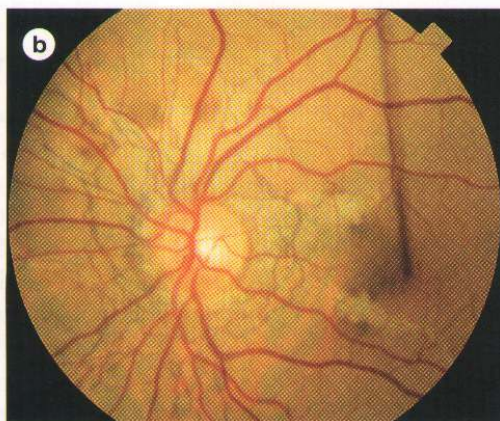
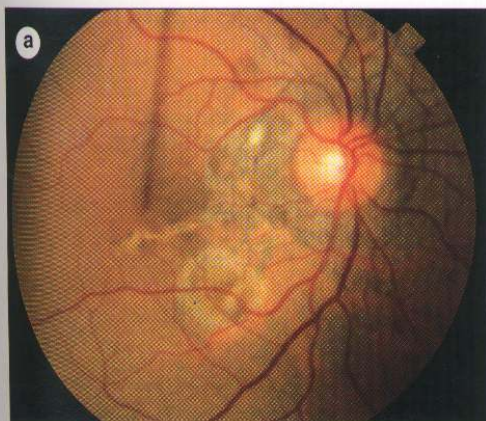


Fig. 13.96
(a and c) Angioid streaks and CNV;
(b and d) angioid streaks alone (see text) (Courtesy of S. Milewski)

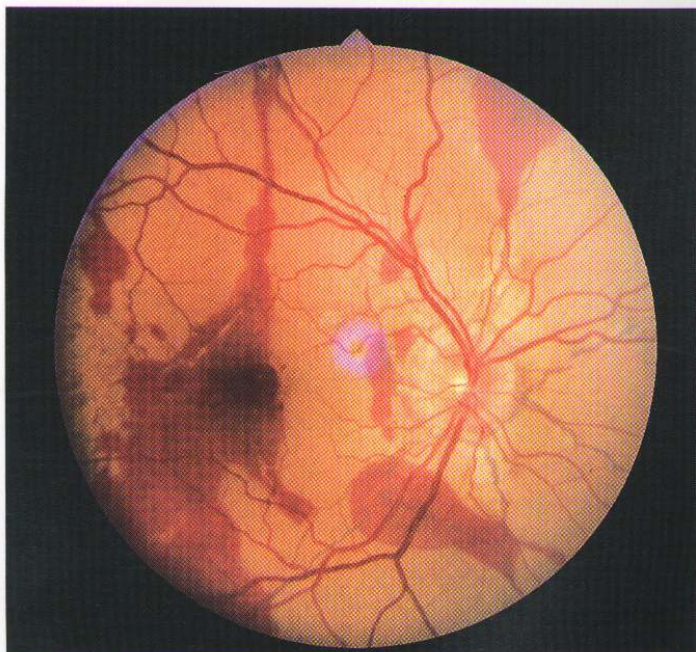


Fig. 13.97
Traumatic choroidal rupture and haemorrhage associated with angioid streaks

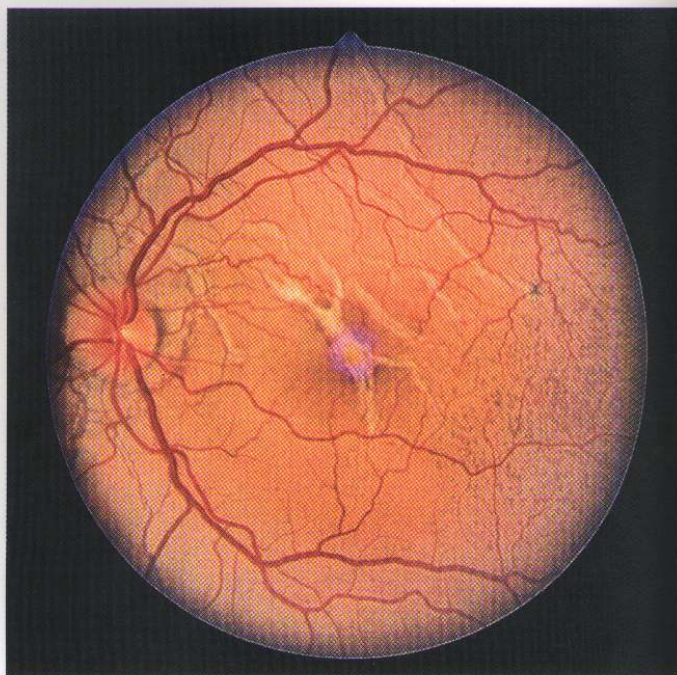


Fig. 13.98
Subretinal scarring following absorption of haemorrhage associated with angioid streaks

Systemic associations

Approximately 50% of patients have one of the following diseases:

1. **Pseudoxanthoma elasticum (PXE)** is by far the most common. Approximately 85% of patients develop ocular involvement, usually after the second decade of life. The combination of the two is referred to as 'Groenblad-Strandberg syndrome' (see Chapter 20).
2. **Ehlers-Danlos syndrome type 6** (ocular sclerotic) is an uncommon association (see Chapter 20).
3. **Other** rare associations include Paget disease and certain haemoglobinopathies.

Choroidal folds

Choroidal folds are parallel grooves or striae involving the inner choroid, Bruch membrane, the RPE and sometimes the sensory retina. Possible mechanisms include choroidal congestion, scleral folding and contraction of Bruch membrane.

Causes

1. **Idiopathic** folds may occur in both eyes of healthy hypermetropic patients with normal or near-normal visual acuity.
2. **Orbital diseases** such as retrobulbar tumours and thyroid eye disease.

3. **Choroidal tumours** such as melanomas may mechanically displace the surrounding choroid and cause folding.
4. **Ocular hypotony** following filtration surgery, if severe and prolonged.
5. **Miscellaneous** causes include chronic papilloedema, posterior scleritis and scleral buckling for repair of retinal detachment.

Clinical features

1. **Presentation** may be with metamorphopsia although the patient may be asymptomatic. Initially visual dysfunction is caused by distortion of overlying retinal receptors. In long-standing cases, permanent changes may develop in the RPE and sensory retina.
2. **Visual acuity** may be normal or impaired, depending on aetiology and duration.
3. **Fundus**
 - Parallel grooves, usually horizontally orientated (Fig. 13.99a); occasionally vertical, oblique or irregular.
 - The crests (elevated portions) appear paler due to thinning of the RPE and the troughs darker due to RPE compression.
4. **FA** shows alternating hyperfluorescent and hypofluorescent streaks at the level of the RPE (Fig. 13.99b). Hyperfluorescence corresponds to the crests due to increased background choroidal fluorescence showing through the thinned RPE. Hypofluorescence corresponds to the troughs due to blockage of choroidal fluorescence by the compressed RPE (Fig. 13.100).

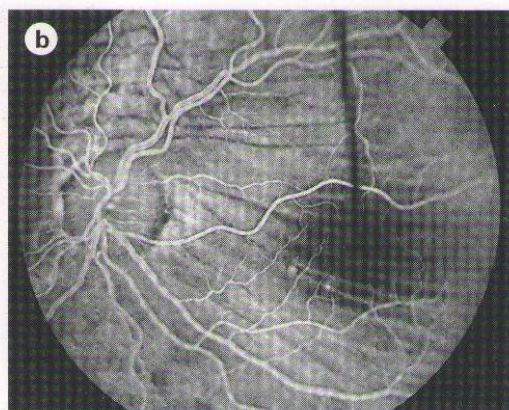
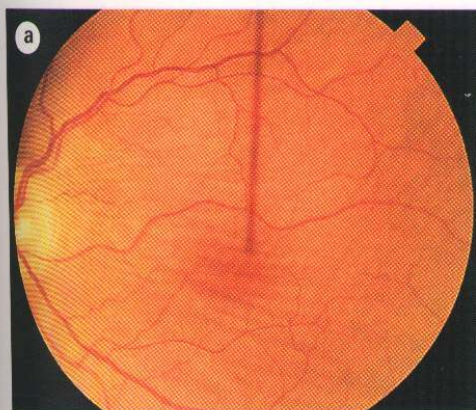


Fig. 13.99
Choroidal folds (see text) (Courtesy
of S. Milewski)

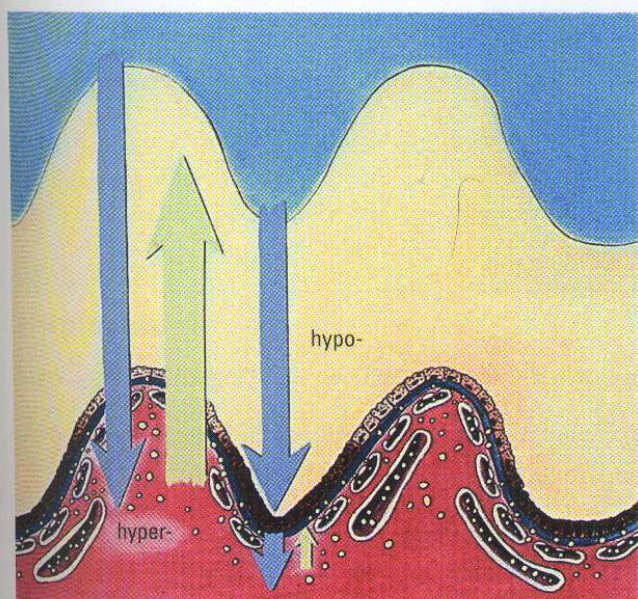


Fig. 13.100
Mechanisms of hypo- and hyperfluorescence in choroidal folds

Drug-induced maculopathies

Antimalarials

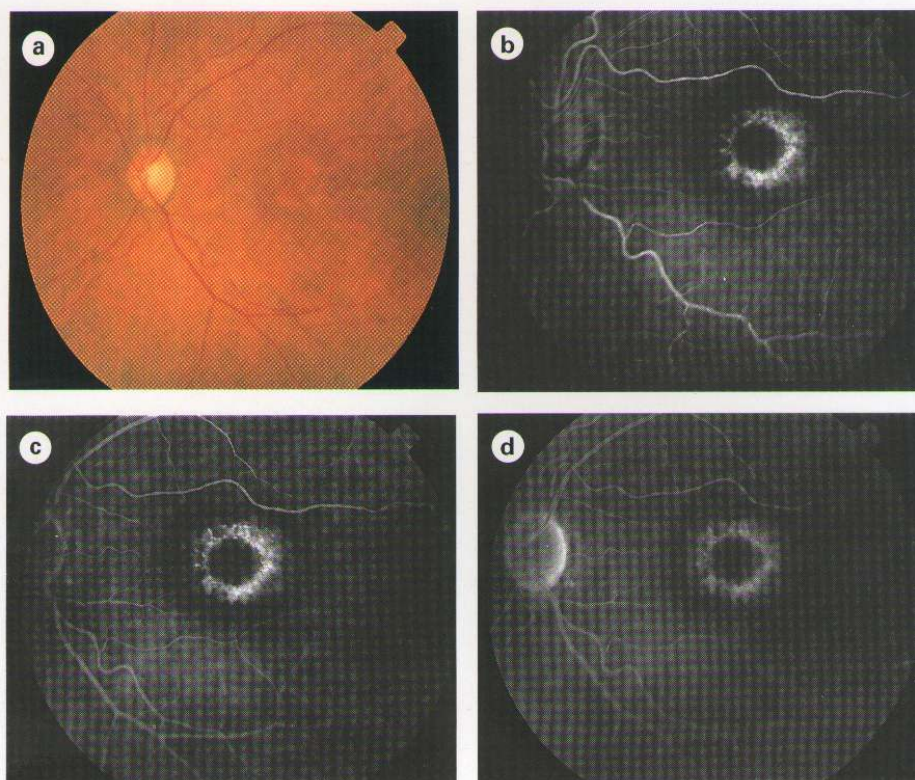
Chloroquine (Nivaquine, Avlocor) and hydroxychloroquine (Plaquenil) are quinolone derivatives used in the prophylaxis and treatment of malaria as well as in the treatment of rheumatoid arthritis, systemic lupus erythematosus and cutaneous lupus. Chloroquine has also been advocated for the treatment of calcium abnormalities of sarcoidosis. Antimalarials are excreted from the body very slowly and are melanotropic drugs that become concentrated in melanin-containing structures of the eye such as the RPE and choroid. The two main ocular side effects of antimalarials are retinotoxicity and corneal deposits. Although uncommon, the retinal changes are potentially serious and the corneal

changes (vortex keratopathy), which are extremely common, are innocuous (see Fig. 5.135).

1. **Chloroquine** retinotoxicity is related to total cumulative dose. The normal daily dose is 250 mg. A cumulative dose of less than 100 g or duration of treatment under 1 year is rarely associated with retinal damage. The risk of toxicity increases significantly when the cumulative dose exceeds 300 g (i.e. 250 mg daily for 3 years). However, there have been reports of patients receiving cumulative doses exceeding 1000 g without developing retinotoxicity. If possible, chloroquine should be used only if other agents are ineffective.
2. **Hydroxychloroquine** is safer than chloroquine and provided the daily dose does not exceed 400 mg the risk of retinotoxicity is negligible. Physicians should therefore be encouraged to use hydroxychloroquine instead of chloroquine whenever possible.

Chloroquine maculopathy

1. **Premaculopathy** is characterized by normal visual acuity but loss of the foveal reflex. This is followed by the development of fine granular changes at the macula which may be associated with mild abnormalities of colour vision and small scotomas to a red target on the Amsler grid. Premaculopathy is reversible if the drug is discontinued.
2. **Early maculopathy** is characterized by a modest reduction of visual acuity (6/9–6/12). Fundus examination shows a subtle macular lesion characterized by central foveolar pigmentation surrounded by a depigmented zone of RPE atrophy which is in turn encircled by a hyperpigmented ring (Fig. 13.101a). The lesion may be more obvious on FA than ophthalmoscopy because the RPE atrophy gives rise to a 'window' defect (Fig. 13.101b–d). This stage is irreversible even if the drug is stopped.
3. **Established maculopathy** is characterized by moderate reduction of visual acuity (6/18–6/24) and an obvious 'bull's eye' macular lesion.

**Fig. 13.101**

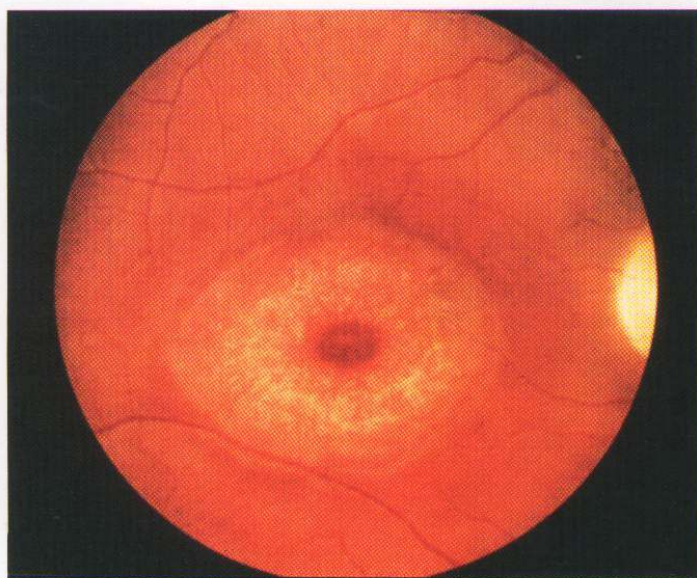
(a) Chloroquine maculopathy; (b–d) FA showing bull's eye maculopathy (see text) (Courtesy of S. Milewski)

4. Severe maculopathy is characterized by marked reduction of visual acuity (6/36–6/60) with widespread RPE atrophy surrounding the fovea (Fig. 13.102).

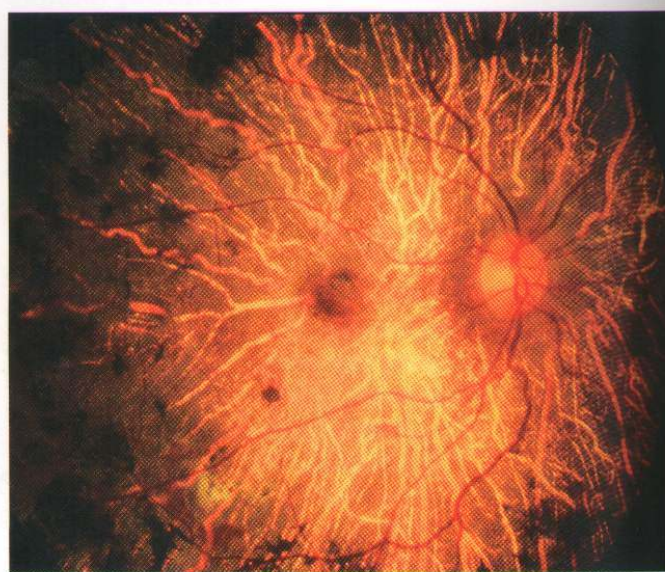
5. End-stage maculopathy is characterized by severe reduction of visual acuity and marked atrophy of the RPE with unmasking of the larger choroidal blood vessels. The retinal arterioles may also become attenuated and pigment clumps develop in the peripheral retina (Fig. 13.103).

Screening

Screening of patients on hydroxychloroquine is unnecessary. In clinical practice chloroquine may also be administered safely to patients without the need for repetitive routine examinations by ophthalmologists or the use of complicated tests. Recording of visual acuity and ophthalmoscopy by the prescribing doctor is all that is required. The patient should be given an Amsler grid to use once a week. If an abnormality is

**Fig. 13.102**

Severe chloroquine maculopathy

**Fig. 13.103**

End-stage chloroquine maculopathy

found, then ophthalmic referral should be sought. The ophthalmologist can then, if necessary, perform more sophisticated tests such as visual fields, macular threshold, colour vision testing, contrast sensitivity, FA and electro-oculography.

Phenothiazines

Thioridazine

Thioridazine (Melleril) is used to treat schizophrenia and related psychoses. The normal daily dose is 150–600 mg. Doses exceeding 800 mg/day for even a few weeks may be sufficient to impair visual acuity and dark adaptation. The clinical signs of progressive retinotoxicity are as follows:

- ‘Salt-and-pepper’ pigmentary disturbance involving the mid-periphery and posterior pole.
- Coarse plaque-like pigmentation and focal loss of the RPE and choriocapillaris (Fig. 13.104).
- Diffuse loss of the RPE and choriocapillaris (Fig. 13.105).

Chlorpromazine

Chlorpromazine (Largactil) is used as a sedative and to treat schizophrenia. The normal daily dose is 75–300 mg. Retinotoxicity may occur with larger doses over a prolonged period and is characterized by non-specific pigmentary granularity and clumping. Other innocuous ocular side effects include yellowish-brown granules on the anterior lens capsule (*see* Fig. 8.21) and corneal endothelial deposits.

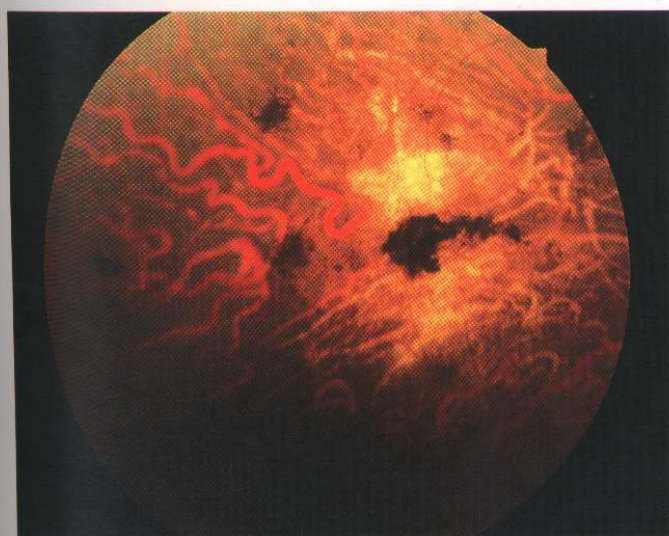


Fig. 13.104
Pigment plaques in thioridazine toxicity

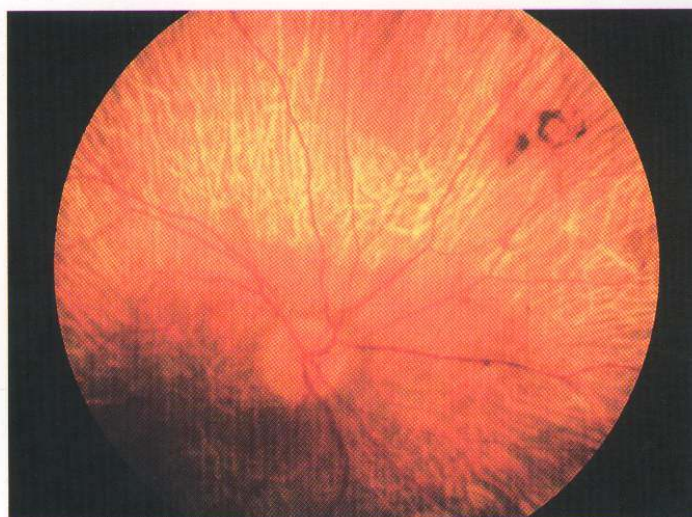


Fig. 13.105
Diffuse atrophy of the RPE and choriocapillaris in severe thioridazine toxicity

Toxic crystalline maculopathies

Tamoxifen

Tamoxifen (Nolvodex, Emblon, Noltan, Tamofen) is a specific anti-oestrogen used in the treatment of selected patients with breast carcinoma. It has few systemic side effects and ocular complications are rare on a normal daily dose of 20–40 mg. Retinotoxicity may occasionally develop in patients on higher doses and is characterized by relatively innocuous, bilateral, multiple, yellow, crystalline, ring-like deposits at the maculae (Fig. 13.106) which persist on cessation of treatment. Other rare ocular side effects are vortex keratopathy and optic neuritis, which are reversible on cessation of therapy. Because maculopathy is rare, routine screening is not warranted.

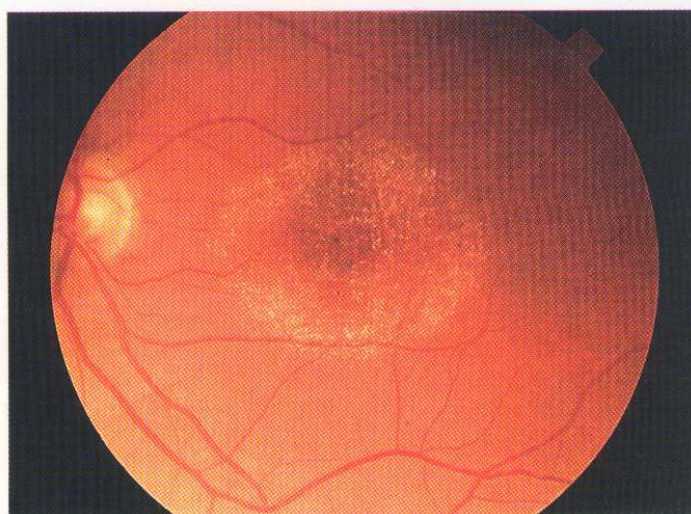


Fig. 13.106
Tamoxifen maculopathy (Courtesy of J. Salmon)

Canthaxanthin

This carotenoid is used to enhance sun tanning. Over prolonged periods it may cause the deposition of bilateral, tiny, glistening, yellow deposits, arranged symmetrically in a doughnut shape at the posterior poles (Fig. 13.107). The deposits are located in the superficial retina and are innocuous.

Methoxyflurane

Methoxyflurane (Penthrane) is an inhalant general anaesthetic. It is metabolized to oxalic acid, which combines with calcium to form the insoluble salt calcium oxalate, which is deposited in tissues including the RPE. Prolonged administration may lead to renal failure and secondary hyperoxalosis. It may also result in the formation of innocuous crystals within the retinal vasculature.

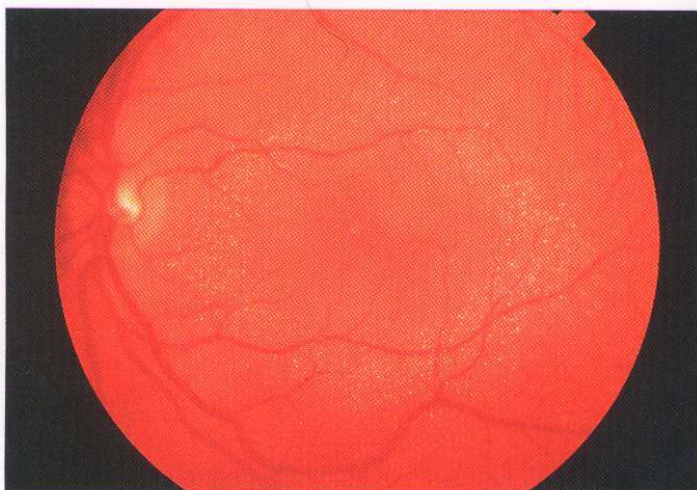


Fig. 13.107
Canthaxanthin maculopathy

Miscellaneous maculopathies

Idiopathic polypoidal choroidal vasculopathy

Idiopathic polypoidal choroidal vasculopathy (posterior uveal bleeding syndrome, multiple serosanguinous RPE detachment syndrome) is an uncommon condition with a predilection for non-white people.

1. Pathogenesis. There is an abnormality of the inner choroidal vessels consisting of a dilated network and multiple terminal aneurysmal protuberances in a polypoidal configuration, with a predilection for the macula and less frequently the parapapillary area. These polypoidal lesions appear to be responsible for episodic leakage and bleeding under the RPE and sensory retina.

2. Presentation is with sudden unilateral visual impairment.

3. Signs

- Serosanguinous detachments of the RPE which may be multiple and variable in size and which may be associated with subretinal lipid (Fig. 13.108).
- In some cases bullous retinal detachment and vitreous haemorrhage may occur.

4. ICG shows the presence of large choroidal vascular complexes with localized terminal polyp-like bulbs (Fig. 13.109) that fill slowly and then leak intensely.

5. Treatment by laser photocoagulation is occasionally required if serosanguinous leakage threatens the fovea.

6. Prognosis is generally good with spontaneous resolution of exudation and haemorrhage.

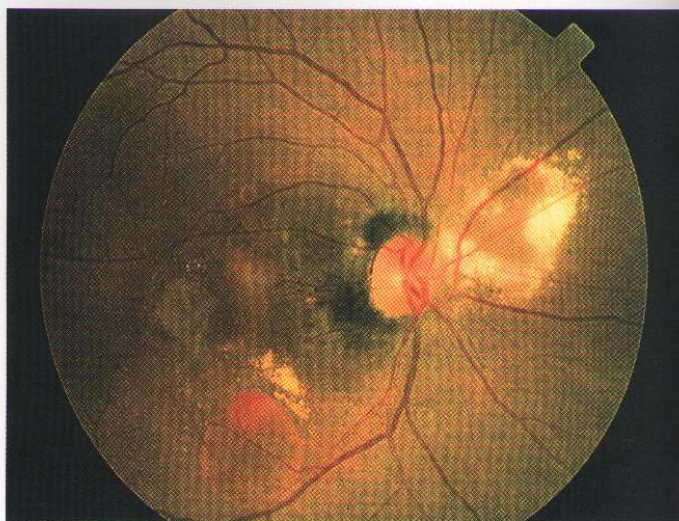


Fig. 13.108
Idiopathic polypoidal choroidal vasculopathy (Courtesy of R. Spaide)

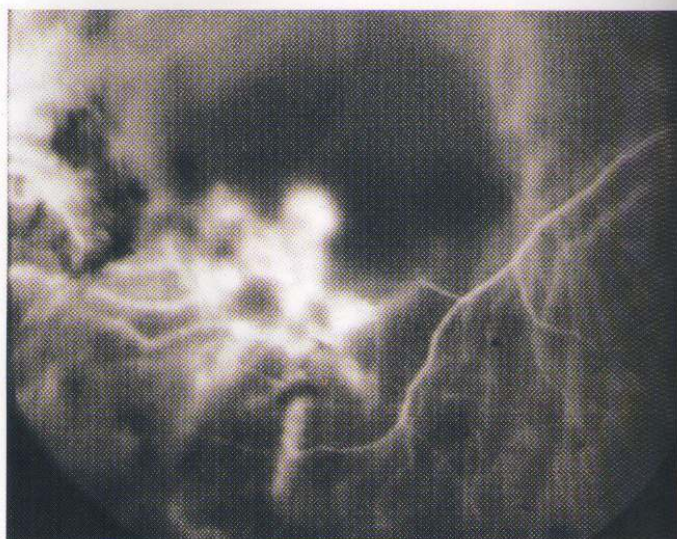


Fig. 13.109
ICG of idiopathic polypoidal choroidal vasculopathy showing hyperfluorescent polyp-like bulbs (Courtesy of V. Tanner)

Maculopathy in optic disc pit

Optic disc pit is a rare, usually unilateral, congenital anomaly.

1. Signs

- Visual acuity is normal in the absence of maculopathy.
- The optic disc is larger than normal and contains a round or oval pit of variable size which is usually located temporally (Fig. 13.110), but may be central.

2. **Visual field defects** are common and may mimic those due to glaucoma.

3. **FA** of the pit shows early hypofluorescence and late hyperfluorescence (Fig. 13.111b).

4. **Maculopathy** (Fig. 13.111a and c) occurs in about 45% of eyes with non-central pits, most frequently at about puberty. Subretinal fluid is thought to be derived either from the vitreous or the subarachnoid space. A less likely source is leakage from abnormal blood vessels within the base of the pit (Fig. 13.111d). Initially there is a schisis-like separation of the inner retinal layers which communicates with the pit. This is followed by detachment of the outer retinal layers from the RPE.

5. Treatment options

- Observation** at 3-monthly intervals for evidence of spontaneous resolution, which occurs in up to 25% of cases.
- Argon laser photocoagulation** may be considered if visual acuity is deteriorating. The burns are applied along the temporal aspect of the disc. The success rate is about 30%.

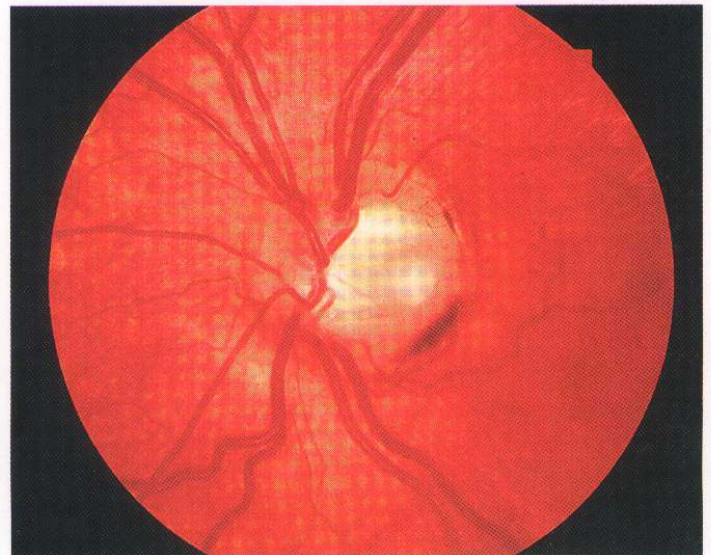


Fig. 13.110
Congenital optic disc pit

c. **Pars plana vitrectomy** with air–fluid exchange, postoperative prone positioning and subsequent laser photocoagulation may be considered if laser alone is unsuccessful. The success rate is about 65%.

d. **Gas injection** (C_3F_8) without vitrectomy may also be successful.

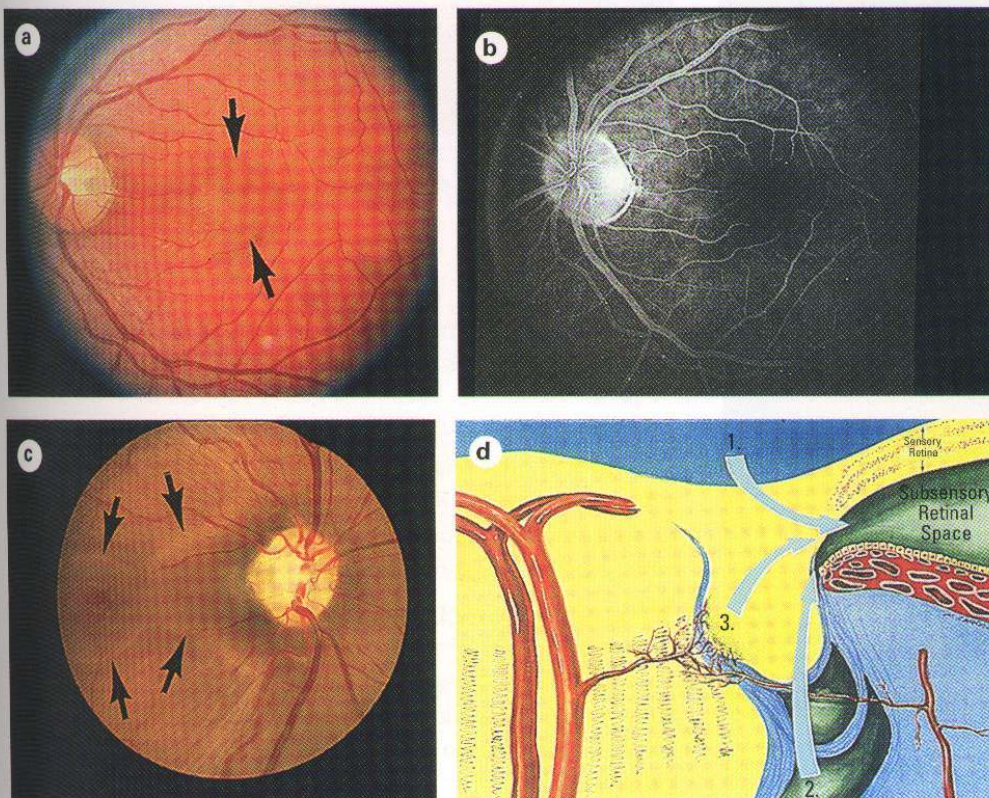


Fig. 13.111
Maculopathy associated with congenital optic disc pit (see text)
(Courtesy of Wilmer Eye Institute)

Solar maculopathy

Solar maculopathy is caused by photochemical effects of solar radiation as a result of directly or indirectly looking at the sun.

1. **Presentation** is 1–4 hours after solar exposure with unilateral or bilateral impairment of central vision, metamorphopsia or central scotomas.
2. **Signs**
 - Visual acuity is variably impaired according to the extent of damage.
 - Initially there are small, unilateral or bilateral, yellow foveolar spots with a grey margin (Fig. 13.112).
 - This is followed about 2 weeks later by circumscribed RPE mottling (Fig. 13.113) or a lamellar hole.
3. **Prognosis** is usually good with improvement of visual acuity to normal or near-normal levels within 6 months although mild symptoms may persist.

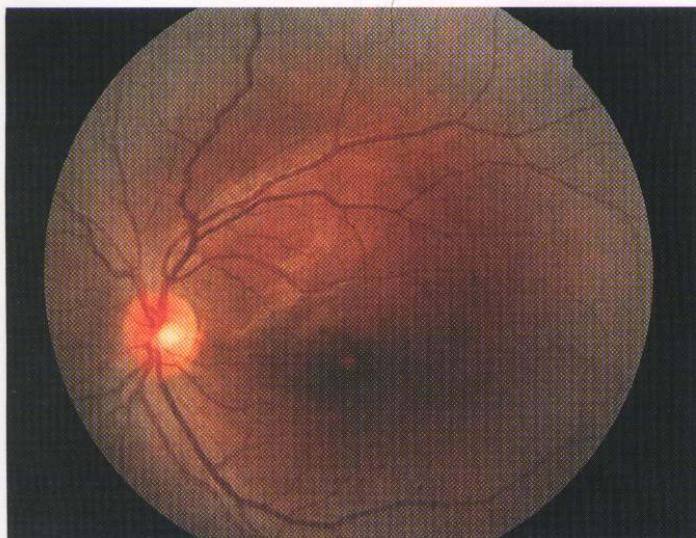


Fig. 13.112
Acute solar maculopathy showing a small yellow foveolar spot

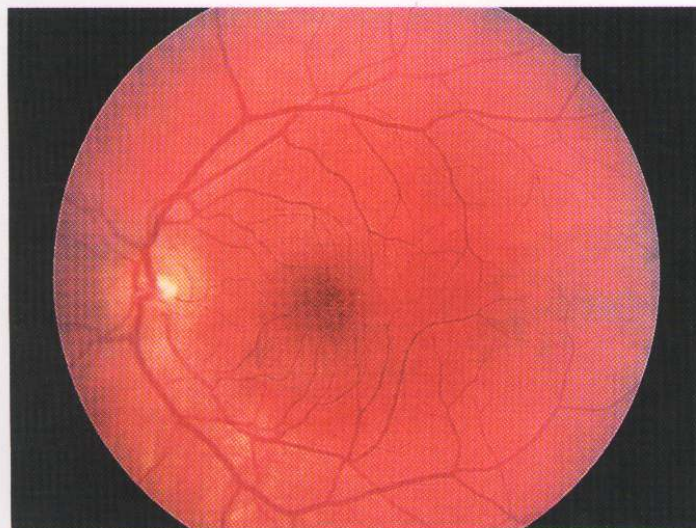


Fig. 13.113
Late solar maculopathy showing mild RPE mottling

Cancer-associated retinopathy

Cancer-associated retinopathy (CAR) is a rare autoimmune photoreceptor destruction in which patients develop visual disturbances in the absence of ocular metastases or involvement of visual pathways. CAR primarily occurs in patients with small cell lung carcinoma and occasionally other epithelial tumours. In 50% of cases it is the initial manifestation of the underlying tumour.

1. **Presentation** is with gradual-onset dimming of vision associated with shimmering photopsiae, bizarre visual images and acute-onset night-blindness (nyctalopia).
2. **Signs**
 - Progressive, bilateral, sometimes asymmetrical, visual loss, ring scotomas and colour vision abnormalities.
 - The fundus may appear normal or show arteriolar attenuation and occasionally optic atrophy (Fig. 13.114).
3. **ERG** is subnormal and may become extinguished.

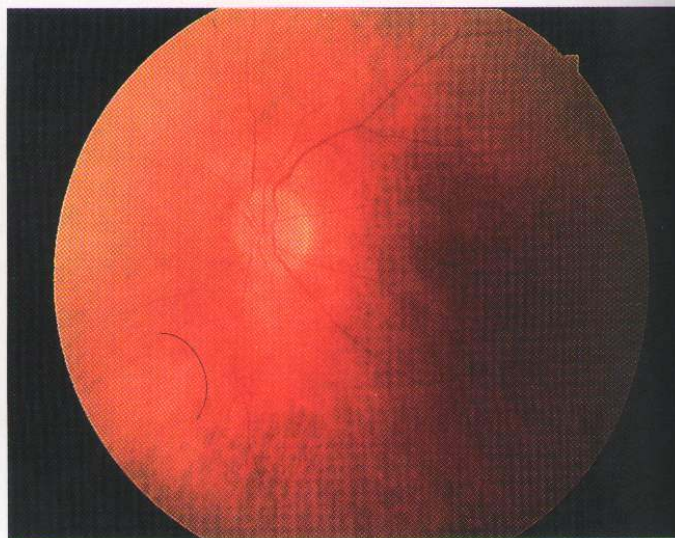


Fig. 13.114
Arteriolar attenuation in cancer-associated retinopathy

4. **Treatment** options include systemic steroids, intravenous immunoglobulins and plasmapheresis but the prognosis is poor.

NB: Melanoma-related retinopathy (MAR) is similar to but rarer than CAR and occurs in patients with established metastatic cutaneous melanomas.

Valsalva maculopathy

Valsalva maculopathy is a rare condition caused by transmission of sudden and severe increase in intrathoracic or intra-abdominal pressure to the eye resulting in intraocular bleeding.

1. **Signs.** Small, unilateral or bilateral, macular haemorrhages which are most frequently pre-retinal (Fig. 13.115).
2. **Prognosis** is excellent with spontaneous resolution without sequelae.

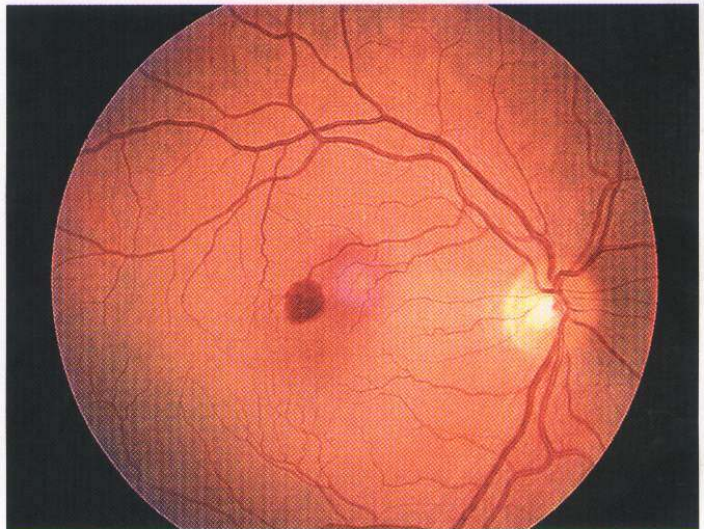


Fig. 13.115
Valsalva maculopathy